

Obturator Hernia is an Extremely Rare Type of Hernia with Relatively High Mortality and Morbidity

Dr Brahmjeet Atrish

Junior Resident Igmc Shimla

Abstract

Obturator Hernia Is A Rare Condition In Which Abdominal Contents Protrude Through The Obturator Canal

Obturator Hernias Have Been Reported For 0.05% -1.4% Of All Hernias

Referred To As The “ Little Old Lady’s Hernia “, Obturator Hernia Is More Common In Elderly Females And Post Pregnancy Patients Due To The Greater Width Of The Pelvis, Larger Obturator Canal, And Increased Laxity Of The Pelvic Tissues

The Symptoms Are Usually Signs Of Partial Bowel Obstruction And Abdominal Pain That Is Referred Along The Obturator Nerve To The Knee (Howship – Rhomberg Sign).

A Ct Scan Of The Pelvis And Upper Thigh Region Can Be Helpful As A Diagnostic Tool

The Only Treatment For Obturator Hernia Is Surgery

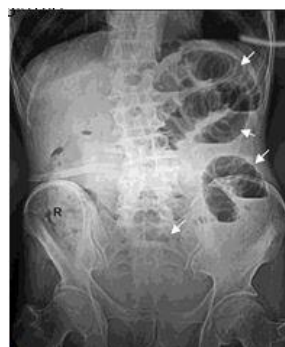Keywords: Hernia, surgery, abdominal obstruction

Introduction

Obturator hernia is an extremely rare type of hernia with relatively high mortality and morbidity
Diagnosis an obturator hernia is challenging due to non specific signs and symptoms

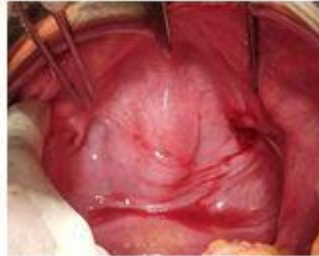
CASE HISTORY

80 Yrs Old Female Patient Presented With Complaints Of Non Passage Of Stools And Flatus For 7 Days Associated With Nausea And Billous Vomiting 4-5 Episodes And Intermittent Colicky Left Lower Abdominal Pain That Radiated To Left Thigh On Examination Abdomen Distended, Tenderness Present In Left Lower Quadrant And Increased Bowel Sounds Plain Abdominal Xray Revealed Small Bowel Obstruction And Air Fluid

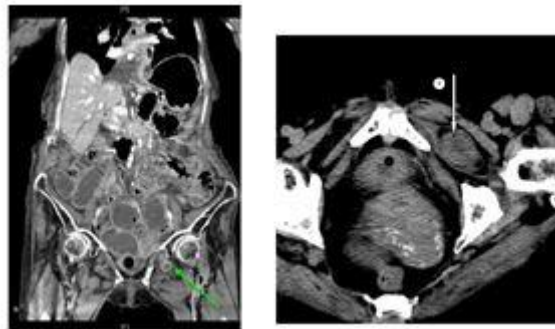


Operative Finding

Midline Incision Given, Small Intestine Was Grossly Dilated. Small Bowel Loop Approximately 2cm Was Obstructed In Left Obturator Foramen Gut Reduced By Manual Traction , Obstructed Segment Was Grossly Normal Retrograde Decompression Was Done. Defect In Obturator Foramen Closed With Silk 1-0



Cect Abdomen Showing The Left Obturator Hernia



Discussion

Obturator Hernia Is A Rare Condition In Which Abdominal Contents Protrude Through The Obturator Canal Obturator Hernias Have Been Reported For 0.05% -1.4% Of All Hernias Referred To As The “ Little Old Lady’s Hernia “, Obturator Hernia Is More Common In Elderly Females And Postregnancy Patients Due To The Greater Width Of The Pelvis, Larger Obturator Canal, And Increased Laxity Of The Pelvic Tissues The Symptoms Are Usually Signs Of Partial Bowel Obstruction And Abdominal Pain That Is Referred Along The Obturator Nerve To The Knee (Howship – Rhombert Sign). A Ct Scan Of The Pelvis And Upper Thigh Region Can Be Helpful As A Diagnostic Tool The Only Treatment For Obturator Hernia Is Surgery The Mortality Rate Can Be As High As 70% When Associated With Perforation And Sepsis

Conclusion

Obturator Hernia As A Cause Of Bowel Obstruction Is A Rare Surgical Condition
Obturator Hernia Should Be Highly Suspected When Assessing Elderly Female Patients With Bowel Obstruction Having Intermittent Symptoms Of Medial Thigh Pain
Delayed Diagnosis And Treatment May Result In Higher Morbidity And Mortality

REFERENCES

1. Bailey and Love’s Short Practice of Surgery Volume 2, 27th Edition Sabiston Textbook of Surgery 21st Edition
2. Lo C.Y., Lorentz T.G., Lau P.W. Obturator hernia presenting as small bowel obstruction. American



Journal of Surgery. 1994;167:396–398 Bryant T.L., Umstot R.K., Jr. Laparoscopic repair of an incarcerated obturator hernia. Surgical Endoscopy. 1996;10(4):437–438.