

Green Synthesis of Silver Nanoparticles From bark Extract to Detect Anti-Ulcer Activity in Swiss Albino Rats

Kalpana P. Ghoshal¹, Ajay M. Ghatole²

¹Researcher, Department of Botany, Dhote Bandhu Science College, Gondia, INDIA.

²Researcher, Department of Chemistry, J. M. Patel Science College, Bhandara, INDIA

ABSTRACT

The anti-ulcer activity of *Butea monosperma* silver nanoparticles (SNBM) was estimated in Swiss albino rats using ulcers caused by histamine, drugs, and ethanol. The effects of the SNBM at the doses of 300 and 550 mg/kg per os (p.o.) were compared with those of the reference pharmaceuticals, famotidine (35 mg/kg b.w.), and revealed substantial safeguards against ulcers generated by indomethacin and histamine. Additionally, the extract demonstrated excellent resistance against stomach ulcers brought on by ethanol. In addition, in ethanol-induced stomach ulceration, SNBM drastically lowered the spike in lipid peroxide level [(Thiobarbituric acid reactive substances (TBARS))] and restored the altered glutathione level. According to the study, SNBM demonstrates anti-ulcer efficacy by enhancing the gastric mucosa's antioxidant capacity and minimizing mucosal damage.

KEYWORDS: Silver Nanoparticles; *Butea Monosperma*; Anti-Ulcer Activity.

Introduction

Butea monosperma (Lam) Taub (*Butea frondosa*) forest flame commonly known as Palash is a traditionally used medicinal plant, distributed in tropical and subtropical parts of the Indian subcontinents and Southeast Asia. It is a small-sized dry season deciduous tree up to a height of 15 m tall with a crooked trunk, and irregular branches with clothed shoots with grey or brown pubescence. The seeds, bark, flowers, leaves, and gum all have medicinal properties. Gum is an external astringent; leaves are diuretic and have aphrodisiac properties. Seeds are purgative, ophthalmic, anti-helminthic, rubefacient, depurative, and tonic, useful in herpes, skin disease, ringworm, arthritis, and diabetes. Bark extract displays significant antimicrobial activities (1). It also shows antifungal, anti-inflammatory, hypoglycaemic, and anthelmintic properties (2). The key elements of plants are butrin, flavonoids, steroids, glycosides, and aromatic chemicals. The current research investigation has been underway with an aim of discovering the therapeutic qualities along with assessing the anti-ulcer activity of SNBM in several models in Swiss albino rats. Ulcers are triggered because of the difference between aggressive and defensive factors of the gastric mucosa (3). The offensive factors are pepsin and gastric acid whose proteolytic effect is buffered by mucin secretion, mucosal glycoprotein, cell shedding, cell proliferation, and prostaglandins (4). The secretion of stomach acid is inhibited by a variety of medicinal drugs, including plant extracts, which are also used to boost the mucosal defense system by either enhancing the creation of mucus, which protects the surface epithelial cells or by interfering with the PG synthesis (5). Different chemical substances can cause gastrointestinal damage (6). Gastrointestinal lesions are linked to lipid peroxidation and oxygen-derived free radicals (7). Antioxidants stop the development of lesions brought on by different ulcerogenesis (8). Measurements of gastro-protective behavior have been performed using ethanol-induced gastric ulcers extensively. By lowering endogenous glutathione and prostaglandin levels, reducing gastric mucosal blood flow, developing less mucus in the stomach, increasing ischemia, gastric vascular permeability, acid "back diffusion," histamine release, sodium and potassium efflux, calcium influx, free radical

generation, and leukotriene production, ethanol results in ulcers (9). Investigations demonstrate that oxygen-derived free radicals have a significance in both acute and chronic ulceration, and neutralizing these radicals can have an important influence on the process of wound healing. Free radicals generated via ethanol elevate lipid peroxide levels and reduce cysteine, which requires amino acids to synthesize glutathione, which lowers glutathione levels (10). The gastrointestinal mucosa of rats (11) and humans both have substantial amounts of reduced glutathione. This glutathione serves as crucial to retaining the integrity of the mucosa; when glutathione levels in the gastric mucosa are low, mucosal ulceration develops (12). In comparison to control animals, oral administration of ethanol results in significantly higher levels of lipid peroxide, severe gastrointestinal injury, and Thio-barbituric acid reactive substance (TBARS). The gastrointestinal mucosa's glutathione content dropped (13). When compared to the animals that were not given any kind of therapy, the EEBM considerably decreased the elevated level of lipid peroxide and normalized the modified glutathione level. It's speculated that EEBM's antioxidant action is what causes it to safeguard against ethanol-induced stomach damage (14). An earlier study claimed that certain *Butea* species had anti-ulcer characteristics (15). Gallic acid and ellagic acid were found in this therapeutic plant after phytochemical analysis (16). Ellagic acid and Gallic acid were identified as the key elements of the EETP by TLC and HPTLC (phytochemical analysis). A polyphenol that is commonly found, ellagic acid A, has been researched and reported to have excellent anti-inflammatory qualities (17). It also significantly reduces the production of stomach lesions associated with stress and suppresses acid secretion. Its ability to lower the activity of H^+ and K^+ ATPase could assist in explaining this action (18).

Materials and Methods

The Plant *Butea monosperma* bark was collected in March 2022 from Gondia District of Maharashtra, India. The bark was identified by Herbarium specimens kept in the Department of Botany, Dhote Bandhu Science College, Gondia affiliated to Rashtrasant Tukadoji Maharaj Nagpur University Nagpur, A voucher specimen (BM/HS/DBSC/12.03.2022-4) is preserved there for future reference. To get rid of any contaminants, the collected material was thoroughly cleaned under running tap water and then rinsed with triple distilled water. It was then allowed to air-dry before being chopped using an electrical grinder into a fine powder for use in the experiments. This yielded a consistent mixture. To achieve an around 1.2 percent (W/W) concentrated extract, 0.29 grams of this combination were added to a 100 mL beaker and soaked in triple distilled water. This extract acquired a vivid orange color after it was filtered using Whatman filter paper No. 42 and allowed to stand for 24 hours. The extract was kept cold to facilitate further testing. Every substance utilized in the examination was as pure as could be found. Potassium bromide (KBr) came from Sigma, while analytical reagent-grade silver nitrate ($AgNO_3$) was shipped from Mumbai, India. The laboratory itself produced the triple-distilled water that was used in the synthesis procedure.

Preparation of the extract and synthesis of AgNPs (silver nanoparticles).

The sample underwent extraction using 90% ethanol employing a Soxhlet extraction apparatus, and subsequently, the solvent was completely evaporated under pressure to produce a semi-solid mass with an approximate yield of 7.5%. Through qualitative analysis, which demonstrated the presence of flavonoids, tannins, and steroids (19), and thin-layer chromatography with real markers, the chemical constituents of the extract were determined. Additionally, to fabricate silver nanoparticles, the extract (1 mL) was combined with 6 mL of a 1mM $AgNO_3$ solution prepared in water at room temperature. This mixture was then stored in darkness for 24 hours. After 14 hours, a solution with a brown-yellowish hue was obtained, confirming the creation of silver nanoparticles (AgNPs). This formation was verified through Ultraviolet-visible spectroscopy (UV-Vis) studies. The purified AgNPs were collected after repeated washing of concentrated slurry. The collected AgNPs were then air-dried and kept in the refrigerator. A weighed amount of about 0.025% was kept in the carboxy methyl cellulose (CMC) before administering doses.

Animals

Swiss albino rats of either sex, weighing 180-200 g, were first fed a traditional pellet diet and free access to water before being subjected to additional research. Gastric ulcers produced by indomethacin (20). The test rats were kept on a 12-hour water fast and an 18-hour fast. ho were split up into four groups (n = 6). Group 1 served as the vehicle control and had its CMC delayed by 0.025%. The reference medication, famotidine, was delivered to Group 2 (35 mg/kg p.o. [mg of a drug per kg of (patient's body mass)/pediatric dose]). Silver nanoparticles from Butea monosperma (SNBM) were given to Group 3 and Group 4 animals one hour before the indomethacin administration (20 mg/kg p.o.) at doses of 300 and 550 mg/kg, respectively. After an hour, the animals were slaughtered, and the stomachs, along with the more pronounced curve, were opened and thoroughly studied. The following scoring system (Table 1) was used for allocating a grade to the ulcer.

TABLE 1. ULCER GRADING AS PER THE SCORE.

Grade	Description
0	Ordinary mucosa
0.5	blushing
1.0	Spot ulcer
1.5	Bleeding streaks
2	Ulcers larger than 3mm but smaller than 5mm
2.5	Ulcers >5mm

Histamine-induced ulcers (21).

Group 1 underwent the same procedure. They were kept without food for 18 hours and without water for 12 hours. Six rats were gathered and divided into four groups. Group 1 received a 0.025% CMC suspension as a vehicle control, while Group 2 was administered the reference medication famotidine (35 mg/kg p.o.) for treatment. Groups 3 and 4 were given SNBM at doses of 300 and 550 mg/kg p.o. respectively. After an hour of receiving the reference and test medications, the animals were administered histamine at a dose of 10 mg/kg. The animals were subsequently killed, the stomachs were opened along the larger curvature, and they underwent comprehensive examination after having been rinsed with normal saline. The stomach mucosa was examined and graded as shown in Table 1 above.

Ethanol-induced gastric ulceration (22).

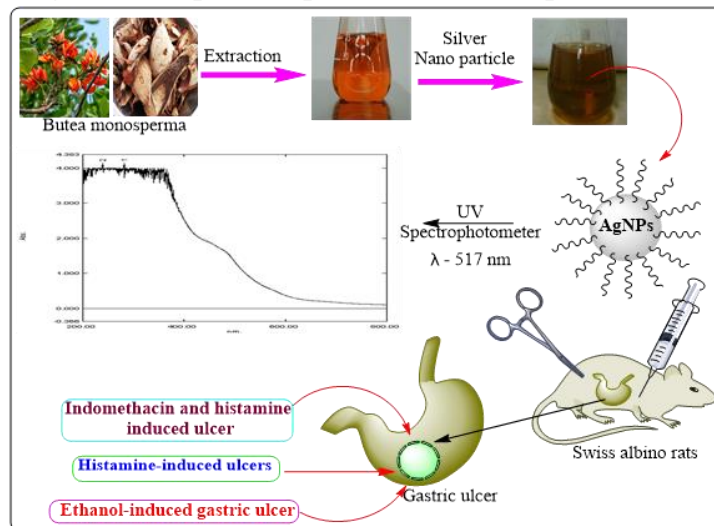
Out of the four animal groups (n = 6), Group 2 was administered omeprazole at the suggested dose (10 mg/kg p.o.), while Group 1 was provided with a 0.025% CMC suspension as the vehicle control. Oral SNBM doses of 300 and 550 mg/kg were given to groups 3 and 4, respectively. The animals were given ethanol orally at a dose of 1 mL/200 g after ingesting the reference drug and the last dose of EEBM (Ethanollic Extract of Butea monosperma). After an hour, the animals' stomachs had been removed along the bigger curvature to check for ulcers, and they were then gently put to death by cervical dislocation. Using a Potter-Elvehjam homogenizer, the fundic mucosal part of the stomach was homogenized (5%) in ice-cold 0.9% normal saline. Following centrifugation of the homogenate at 800 rpm for 10 minutes and at 12000 rpm for 15 minutes, the mitochondrial fraction was utilized to measure lipid peroxide and glutathione levels. Lipid peroxidation TBARS was assessed using the Ohkawa technique (23), and Ellman's reaction with DTNB (5-5-dithio-bis-2-nitrobenzoic acid) was employed to confirm glutathione.

Result and Discussion

The aim of this study was to assess the anti-ulcer activity of the EEBM across different ulcer models. Indomethacin, a powerful inhibitor of prostaglandin (PG), and suppression of PG synthesis by indomethacin correspond with the early stages of damage to mucosal, parietal, and endothelial cell membranes. There is a correlation between gastric

acid secretion and the emergence of mucosal ulcers triggered by indomethacin. The EEBM demonstrated substantial safety against indomethacin-induced stomach ulcers and considerably reduced the ulcer index. Furthermore, EEBM has demonstrated significant efficacy in the treatment of histamine-induced ulcers. Histamine is considered to cause stomach ulceration via increasing gastric acid output and vasospastic action(24)

Figure 1. Graphical representation of the present work.



Indomethacin and histamine-induced ulcer.

The impact of SNBM on ulceration induced by indomethacin and histamine was investigated, and the findings are detailed in Table 2 and Table 3. The synthesized SNBM notably reduced ulceration resulting from indomethacin and histamine. Extracts at doses of 300 and 550 mg/kg displayed 32.23% and 51.31% protection ($p < 0.05$), respectively, against indomethacin-induced stomach ulcers, while famotidine exhibited 63.15% protection ($p < 0.05$). For histamine-induced ulceration, EEBM at 500 mg/kg provided 55.42% protection, whereas famotidine (30 mg/kg) offered 65.15% protection.

ANOVA and Dunnet's test were implemented for calculating statistical significance ($* p < 0.05$ indicated significance in comparison to the indomethacin-treated group). The data is represented as mean \pm S.E.M.

TABLE 2. RATS' ULCERATIONS CAUSED BY INDOMETHACIN AND THE IMPACT OF BUTEA MONOSPERMA ETHANOL EXTRACT (EEBM).

Treatment	Dose (mg/kg)	Ulcer index	Percentage inhibition
Normal	--	00	100
Indomethacin + vehicle	20	15.5 \pm 1.5	--
Indomethacin + famotidine	35	6.1 \pm 0.8*	65.15
Indomethacin + SNBM	300	10.5 \pm 1.0*	35.32
Indomethacin + SNBM	500	7.5 \pm 0.5*	55.13

TABLE 3. RAT ULCERATION TRIGGERED BY HISTAMINE: THE INFLUENCE OF BUTEA MONOSPERMA ETHANOL EXTRACT.

Treatment	Dose (mg/kg)	Ulcer index	Percentage inhibition
Normal	---	00	100
Indomethacin + vehicle	20	15.5 \pm 1.5	---
Indomethacin + famotidine	35	5.9 \pm 0.7*	71.15
Indomethacin + SNBM	300	15.6 \pm 1.0*	35.72

Indomethacin + SNBM 500 10.5+- 0.8* 55.42

Gastric ulcers caused by ethanol.

As per the investigation, SNBM was assessed for its anti-ulcer efficacy towards ethanol-induced stomach ulcers, and the outcomes are outlined in Table 4. When ethanol was taken orally, it caused severe ulceration, markedly raising lipid peroxide levels and sharply lowering glutathione levels. In the model of ethanol-induced ulcers, SNBM notably decreased both the occurrence and severity of ulcers. EETP orally administered at 550 mg/kg b.w (Body weight) offered 52.52% protection, while the reference medication omeprazole provided 59.92% protection. Animals receiving EEBM orally at a dosage of 550 mg/kg b.w significantly decreased the thiobarbituric acid reactive substance from 4.61(±0.23) to 2.38(±0.17) % (p < 0.05).

TABLE 4. THE IMPACT OF BUTEA MONOSPERMA ETHANOL EXTRACT ON ETHANOL-INDUCED ULCERATION IN RATS

Treatment	Dose (mg/kg)	Ulcer index	Percentage inhibition	TBARS (nmol of MDA/mg of protein)	Glutathione (nmol/mg protein)
Normal	--	00	100	1.47±0.13	10.4±1.1
Indomethacin + vehicle	--	25.7	---	4.63±0.25	4.5±0.4
Indomethacin + omeprazole	35	10.5	59.94*	1.84±0.16*	5.4±0.5*
Indomethacin + SNBM	300	17.4	33.09*	3.54±0.22*	9.0±0.9*
Indomethacin +SNBM	550	12.4	52.54*	2.40±0.19*	6.9±0.5*

The data were expressed as mean ±S.E.M. and statistical significance was determined using ANOVA and Dunnet's test (p < 0.05 was considered significant).

CONCLUSION

It has been discovered that oxygen-derived free radicals play a part in the process of acute and chronic ulceration, and that scavenging these free radicals can help heal these ulcers. Ethanol induced free radical production raises lipid peroxide levels while decreasing cysteine, which is necessary for glutathione synthesis, lowering glutathione levels (25). Reduced glutathione is abundant in the stomach mucosa of rats (26) and humans. Glutathione is necessary for mucosal integrity, and glutathione deficiency in the stomach mucosa causes macroscopic mucosal ulceration (27). Compared to the control animals, oral ethanol administration significantly elevated the lipid peroxide (TBARS) level and induced severe stomach injury, accompanied by a reduction in the stomach mucosa's glutathione content. In contrast, compared to the untreated mice, the EEBM substantially decreased the heightened lipid peroxide level and reinstated the depleted glutathione level. It's possible that EEBM's antioxidant action is what prevents ethanol from inflicting stomach damage. Additionally, the phytochemical examination of EEBM has established that gallic acid and ellagic acid are the two main constituents. Ellagic acid, one of the commonly found polyphenols, has powerful antioxidant capabilities (28). Due to the suppression of H[±]- and K[±] ATPase activity, it has a notable inhibitory effect on acid secretion and the formation of stress-induced gastric lesions (29). Biochemical investigation findings revealed a sizable antiperoxidative impact. The current study thus comes to the

conclusion that the EEBM (Ethanollic Extract of *Butea monosperma*) has demonstrated notable anti ulcerous effect by boosting the gastric mucosa's antioxidant potential and *thereby* minimizing mucosal damage.

Acknowledgements

Authors are thankful to Institutional Head Dhote Bandhu Science College, Gondia for providing access to Laboratory facilities in the Department of Botany and Chemistry.

REFERENCES

1. Gadekar GP, Ghoshal KP. (2012) "Green synthesis of silver nanoparticles from *Butea Monosperma* and their antimicrobial activities", *Bionano. Frontier.* 5(2): p. 7-11.
2. Gadekar GP, Ghoshal KP, Ghatole AM. (2021) "*Butea monosperma* bark extract to its green synthesis of Silver Nanoparticles and their Antioxidant, Total Flavonoid content and Antimicrobial activitie", *Journal of Applied Biological Sciences.* 15(1): p. 64-74.
3. Ghatole AM, Lanjewar KR, Gaidhane MK. (2012) "Syntheses, Characterization, Antimicrobial activity of Copper (II), Zinc (II) and Cobalt (II)Complexes of the bi-dented substituted 2-((E)-2-((2-chloro-6-ethoxyquinolin-3-yl) methyleneamino) thiazol-4-yl)phenol having ON donor sites", *Journal of Pharmacy Research.* 5(5): p. 2758-2762.
4. De S, Aswal VK, Goyal PS, Bhattacharya S. (1999) "Characterization of new gemini surfactant micelles with phosphate headgroups by SANS and fluorescence spectroscopy", *Chemical physics letters.* 303(3-4): p. 295-303.
5. Goyal RK, Sairam K. (2002) "Anti-ulcer drugs from indigenous sources with emphasis on *Musa sapientum*, *Tamrabhasma*, *Asparagus racemosus* and *Zingiber officinale*", *Indian Journal of Pharmacology.* 34(2): p. 100-110.
6. Desai P, MacEwen CJ, Baines P, Minassian DC. (1996) "Epidemiology and implications of ocular trauma admitted to hospital in Scotland", *J Epidemiol Community Health.* 50(4): p. 436-441.
7. Van Kolfshoten AA, Zandberg P, Jager LP, Van Noordwijk J. (1983) "Protection b paracetamol against various gastric irritants in the rat", *Toxicology and applied pharmacology.* 69(1): p. 37-42.
8. Mizui T, Sato H, Hirose F, Doteuchi M. (1987) "Effect of antiperoxidative drugs on gastric damage induced by ethanol in rats", *Life sciences.* 41(6): p. 755-763.
9. Glavin GB, Szabo S. (1992) "Experimental gastric mucosal injury: laboratory models reveal mechanisms of pathogenesis and new therapeutic strategies", *The FASEB journal.* 6(3): p. 825-831.
10. Loguercio C, Taranto D, Beneduce F, del Vecchio Blanco C, De Vincentiis A, Nardi G, et al. (1993) "Glutathione prevents ethanol-induced gastric mucosal damage and depletion of sulfhydryl compounds in humans", *Gut.* 34(2): p. 161-165.
11. Hutchinson TA, Boyd NF, Feinstein AR. (1979) "Scientific problems in clinical scales, as demonstrated in the Karnofsky index of performance status", *Journal of chronic diseases.* 32(9-10): p. 661-666.
12. Siegers CP, Böse-Younes H, Thies E, Hoppenkamps R, Younes M. (1984) "Glutathione and GSH-dependent enzymes in the tumorous and nontumorous mucosa of the human colon and rectum", *Journal of cancer research and clinical oncology.* 107: p. 238-241.
13. Ghatole AM, Lanjewar KR, Gaidhane MK. (2014) "Synthesis And Anti-Microbial Activity Of Some Substituted Bis[2-((E)-2-(4-Benzylideneamino)thiazol-4-yl)4-methylphenol]metal complex", *International Journal of Pharmacy and Pharmaceutical Sciences.* 6(2): p. 142- 146.
14. Ghatole AM, Lanjewar KR, Hatzade KM, Gaidhane MK. (2015) "A Comparative Synthesis of Ring-Substituted 3-(3-Bromo-4-Oxo-4h-Chromen-2-Yl)-4h-Chromen-4-One", *International Journal of Researches In Biosciences, Agriculture & Technology.* (1): p. 89-99.

15. Nadar TS, Pillai MM. (1989) "Effect of ayurvedic medicines on beta-glucuronidase activity of Brunner's glands during recovery from cysteamine induced duodenal ulcers in rats", *Indian Journal of Experimental Biology*. 27(11): p. 959-962.
16. Rao KV, Sreeramulu K, Gunasekar D, Ramesh D. (1993) "Two new sesquiterpene lactones from *Ceiba pentandra*", *Journal of Natural Products*. 56(12): p. 2041-2045.
17. Festa A, D'Agostino Jr R, Williams K, Karter AJ, Mayer-Davis EJ, Tracy RP, et al. (2001) "The relation of body fat mass and distribution to markers of chronic inflammation", *International journal of obesity*. 25(10): p. 1407-1415.
18. Murakami A, Fujita Y. (1991) "Regulation of photosystem stoichiometry in the photosynthetic system of the cyanophyte *Synechocystis* PCC 6714 in response to light intensity", *Plant and cell physiology*. 32(2): p. 223-230.
19. Harborne JB, Harborne JB. (1999) "Phenolic compounds. *Phytochemical Methods*", A Guide to Modern Techniques of Plant Analysis. 1984;: p. 37-99
20. Akah PA, Nwafor SV. Studies on anti-ulcer properties of *Cissampelos mucronata* leaf extract. *Indian J Exp Biol*. 37(9): p. 936-938.
21. Anis KV, Rajeshkumar NV, Kuttan R. (2001) "Inhibition of chemical carcinogenesis by berberine in rats and mice", *Journal of Pharmacy and Pharmacology*. 53(5): p. 763-769.
22. Sladen JA, D'hollander RD, Krahn J. (1985) "The liquefaction of sands, a collapse surface approach", *Canadian geotechnical journal*. 22(4): p. 564-578.
23. Ohkawa H, Ohishi N, Yagi K. (1979) "Assay for lipid peroxides in animal tissues by thiobarbituric acid reaction", *Analytical biochemistry*. 95(2): p. 351-358.
24. Anis KV, Rajeshkumar NV, Kuttan R. (2001) "Inhibition of chemical carcinogenesis by berberine in rats and mice", *Journal of Pharmacy and Pharmacology*. 53(5): p. 763-768.
25. Loguercio C, Taranto D, Beneduce F, del Vecchio Blanco C, De Vincentiis A, Nardi G, et al. (1993) "Glutathione prevents ethanol-induced gastric mucosal damage and depletion of sulfhydryl compounds in humans", *Gut*. 34(2): p. 161-165.
26. Hutchinson TA, Boyd NF, Feinstein AR. (1979) "Scientific problems in clinical scales, as demonstrated in the Karnofsky index of performance status", *Journal of chronic diseases*. 32(9-10): p. 661-666.
27. Siegers CP, Böse-Younes H, Thies E, Hoppenkamps R, Younes M. (1984) "Glutathione and GSH-dependent enzymes in the tumorous and nontumorous mucosa of the human colon and rectum", *Journal of cancer research and clinical oncology*. 107: p. 238-241.
28. Festa A, D'Agostino Jr R, Williams K, Karter AJ, Mayer-Davis EJ, Tracy RP, et al. (2001) "The relation of body fat mass and distribution to markers of chronic inflammation", *International journal of obesity*. 25(10): p. 1407-1415.
29. Murakami A, Fujita Y. (1991) "Regulation of photosystem stoichiometry in the photosynthetic system of the cyanophyte *Synechocystis* PCC 6714 in response to light intensity", *Plant and cell physiology*. 32(2): p. 223-230.
30. Moron MS, Depierre JW, Mannervik B. (1979) "Levels of glutathione, glutathione reductase and glutathione S-transferase activities in rat lung and liver", *Biochimica et biophysica acta (BBA)-general subjects*. 582(1): p. 67-78.