

# Laparoscopic Management of Unruptured Cornual Ectopic Pregnancy

Shruti Haldar<sup>1</sup>, Indrani Haldar<sup>2</sup>

<sup>1,2</sup>Department of Obstetrics and Gynaecology IPGMER & SSKM HOSPITAL, Kolkata, West Bengal

## Abstract

Cornual ectopic pregnancy is a uncommon type of ectopic pregnancy located at the interstitial part of fallopian tube. It accounts for 2%-4% of all ectopic pregnancies. Cornual pregnancies are rare with a mortality rate significantly higher than that of other ectopic pregnancy types. Due to the cornual region's location in the fallopian tube rupture of cornual gestation may lead to massive intraperitoneal bleeding leading to hypovolemia and shock.<sup>1</sup>

A case of unruptured cornual ectopic pregnancy in 27 years female Gravida 2 para 1 managed successfully laparoscopically.<sup>2</sup>

## Background

Cornual pregnancy is uncommon variety of ectopic pregnancy located at interstitial part of fallopian tube. It often pose therapeutic and diagnostic challenge to the obstetrician. Despite of availability of modern diagnostic techniques there is difficulty in it's early diagnosis because of it's location. It is seen in 1/2500-1/5000 of all the pregnancies and 2%-4% of all ectopic pregnancies.<sup>2</sup>

Here is a case of unruptured cornual ectopic pregnancy in 27 years female ,Gravida 2, para 1 managed successfully laparoscopically.<sup>2</sup>

## Case Report

A 27 years old female, gravida 2, para 1 presented to our outpatient department at IPGMER & SSKM HOSPITAL Kolkata, West Bengal, with no complaints and with an estimated gestational age of 6 weeks according to her last menstrual period, she had a previous history of submucosal myoma 3 years back for which she underwent laparoscopic myomectomy.

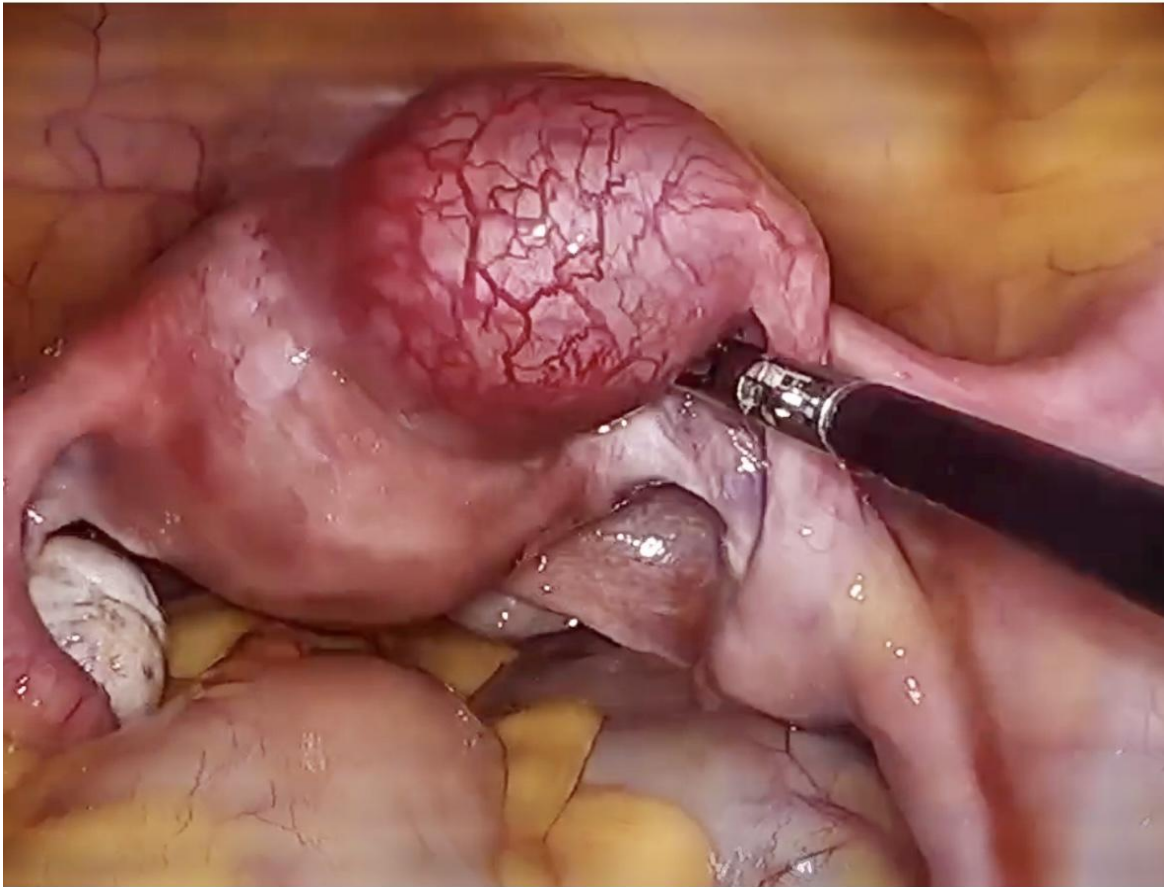
Her beta hcg level has been 95,000 mIU/ml. However ultrasonography done showed no intrauterine pregnancy or other ectopic pregnancy.

However beta hcg was repeated a day after which showed 120,768 mIU/ml.

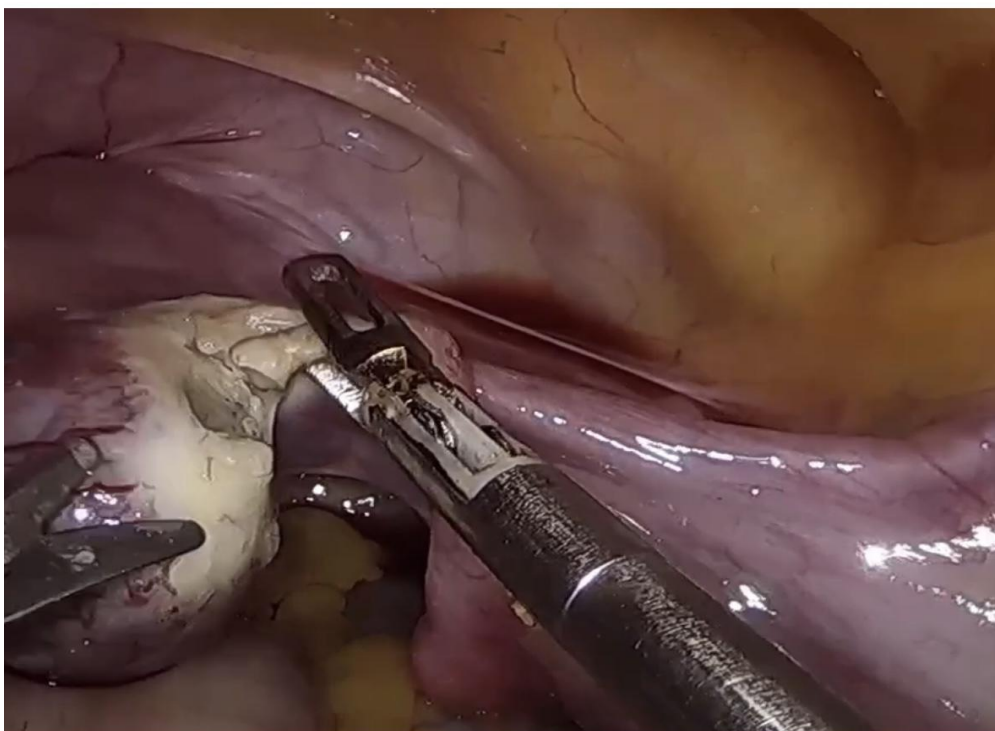
Diagnostic laparoscopy was performed on the next day to rule out cornual pregnancy if any, at laparoscopy we found 5 cm mass in the right uterine Cornua (Fig1.).

The other pelvic organs were significantly normal.

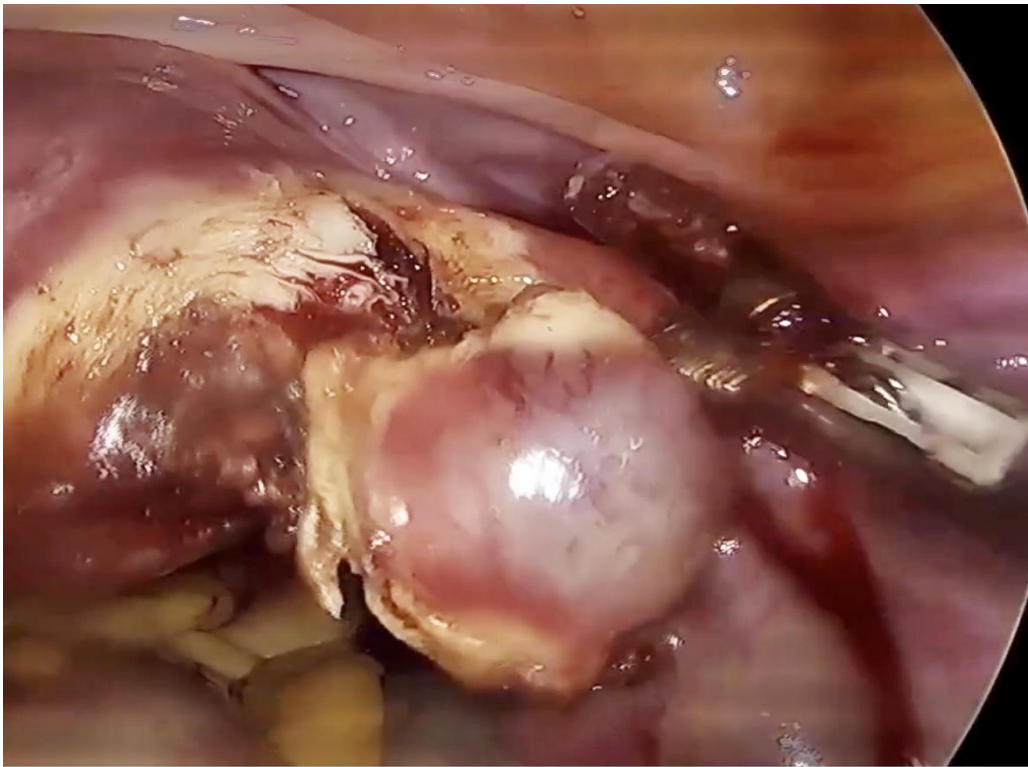
An incision was made in the right cornua using monopolar scissors and the gestation was expressed through this incision (Fig2&3).



**Fig 1 Right cornual unruptured ectopic pregnancy**



**Fig 2. Incision in the right uterine cornua.**



**Fig 3. Expression of gestation sac .**

The sample was sent for histopathological examination which showed the presence of evolutionary pregnancy of 6-7 weeks

In postoperative period her beta hcg was repeated after 2 days which showed level of 5467 mIU/l .

The patient was discharged on day 5 and was reviewed in outpatient department with new beta hcg report which was 60 mI/UL.

### **Discussion**

Many cases of laparoscopic cornual resection have been reported in literature, but a specific surgical methodology has not yet been established.<sup>3</sup>

Although that patients who are unstable and are critically (hypotension, severe abdominal bleeding) are likely undergo emergency laparotomy.

But now in recent advances laparoscopic management of ectopic pregnancy is considered to be the gold standard.<sup>4</sup>

### **Conclusion**

Cornual ectopic pregnancies are uncommon, difficult to diagnose and a surgical challenge. Laparoscopic treatment of cornual pregnancy can be safely carried out with good results in an institution with trained laparoscopists and adequate facility.<sup>5</sup>

However this technique is particularly invaluable in difficult cases where the Cornual ectopic pregnancy is poorly demarcated, highly vascular, but because of its overall safety and cost effective adjunct it's often used as a gold standard for the management of ectopic pregnancy.<sup>6</sup>

**References**

1. Ruptured left cornual Ectopic pregnancy: case report *cureus*.2023 Jul 6;15(7):e41449. doi: 10.7559/cureus.41449.
2. Cornual ectopic pregnancy: Laparoscopic management step by step *BMJ Case Rep*. 2018 Mar 28;2018:bcr2017223998. doi: 10.1136/bcr-2017-223998.
3. Bhagavath B, Lindheim SR. Surgical management of interstitial (cornual) ectopic pregnancy: Many ways to peel orange! *Fertile Steril*. 2021;115:1193-4. doi: 10.1016/j.fertnstert.2021.03.016.
4. Malinowski A, Bates SK. Semantics and pitfalls in the diagnosis of cornual/interstitial pregnancy. *Fertil Steril*. 2006;86:4.e11-4. doi: 10.1016/j.fertnstert.2006.03.073.
5. Laparoscopic management of 53 cases of cornual ectopic pregnancy. Selma Ng, Suthar Hamontri, Irene Chua, Bernad Chern, Anthony Siow. doi: 10.1016/j.fertnstert.2008.08.072.
6. A new technique in the laparoscopic resection of cornual ectopic pregnancy: case series. Rebecca Mallick, Tosin Ajala, *Gynaecological Surgery* 13, 147-151(2016).<https://doi.org/10.1007/s10397-016-0950-8>.