

Postmenopausal Bleeding: Confrontation Between Ultrasound Data and Pathological Results

Nadia Marwen¹, Sahla Zrigue², Gurebej Ekram¹, Fatnassi Ridha¹

^{1,3,4}Department of Obstetrics and Gynecology Department Kairouan, University of Ledecine Sousse
Tunisia

²The Regional Health Directorate of Kairouan, Tunisia

Abstract

Introduction: Postmenopausal bleeding (PMB) is a common reason for consultation in gynecology. Endovaginal ultrasound (EVU) represents the first-line paraclinical examination. The objectives of our study were to analyze the sonographic findings in cases of PMB and to assess the correlation between EVU data and histopathological results.

Materials and Methods: We conducted a retrospective, descriptive, and analytical study including patients presenting with PMB, collected in the Department of Gynecology and Obstetrics of Ibn El Jazzar Hospital in Kairouan, over a 10-year period from January 1, 2014, to December 31, 2024.

Results: During the study period, data from 253 patients were collected. The mean age of the patients was 58 years. The mean age at menopause was 49.3 years, and the mean duration of menopause at the onset of bleeding was 8.42 years. EVU was performed in all cases. The sensitivity of EVU in detecting endometrial pathology was 87.52%, with a specificity of 75%, a positive predictive value (PPV) of 89.25%, and a negative predictive value (NPV) of 54%. For an endometrial thickness threshold of 4 mm, the sensitivity of EVU in diagnosing endometrial cancer was 100%, with a specificity of 25.34%, a PPV of 23.48%, and an NPV of 100%.

Conclusion: Given its performance and simplicity, EVU remains the first-line screening examination for the assessment of postmenopausal bleeding.

Keywords: Postmenopausal bleeding , Menopause , Endometrial cancer , Endovaginal ultrasound , Histology.

INTRODUCTION

Postmenopausal bleeding (PMB) is a frequent reason for consultation in gynecology. Approximately 70% of postmenopausal consultations are related to bleeding [1], and 5% of all gynecological investigations concern PMB. This issue tends to increase due to population aging and the frequent use of hormone replacement therapy (HRT).

PMB is defined as any abnormal uterine bleeding occurring after at least 12 months of amenorrhea [2]. Although endometrial atrophy remains the most common cause of PMB, it is mandatory to rule out endometrial cancer in all cases. Endovaginal ultrasound (EVU) currently represents the first-line paraclinical examination for PMB. It allows measurement of endometrial thickness and provides a

semiological description in terms of regularity and homogeneity, which helps orient the diagnosis toward benign or malignant features.

In the presence of sonographic abnormalities, hysteroscopy is indicated. It enables targeted endometrial biopsy and/or the sampling of any intracavitary lesion for histopathological confirmation.

Given this context, we conducted a retrospective, descriptive, and analytical study involving patients presenting with PMB, collected in the Department of Gynecology and Obstetrics at Ibn El Jazzar Hospital in Kairouan, over a 10-year period from January 1, 2014, to December 31, 2024.

The objectives of our study were to analyze the results of sonographic evaluation of PMB and to assess the correlation between EVU findings and histopathological results.

MATERIALS AND METHODS

This was a retrospective, descriptive study involving 253 patients presenting with PMB, collected in the Department of Gynecology and Obstetrics at Ibn El Jazzar Hospital in Kairouan, over a 10-year period from January 1, 2014, to December 31, 2024.

We included patients presenting with uterine-origin PMB occurring after at least one year of amenorrhea. We excluded patients in perimenopause, those who had been menopausal for less than one year, and cases of genital bleeding not originating from the uterus.

Data collection was performed through analysis of hospitalization records, ultrasound images, anesthesia reports, surgical records, and histopathological results. The following information was collected: patient age; personal and family medical history; general and gynecological examination findings; EVU results; diagnostic and/or operative hysteroscopy findings; endometrial biopsy with histological examination; and any surgical treatment with histopathological study.

RESULTS

During the study period, we collected data from 253 patients who met the inclusion and exclusion criteria. The mean age of the patients was 58 years, ranging from 39 to 84 years.

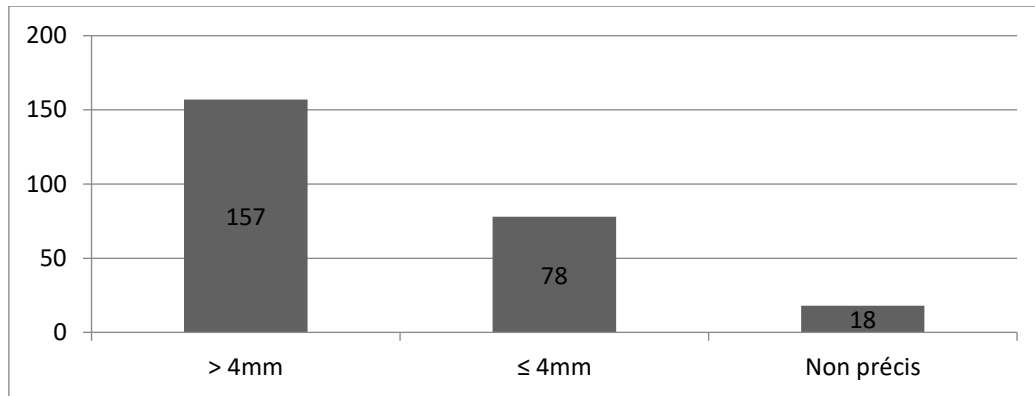
Among the patients, 84 (33.2%) were diabetic, 112 (44.26%) were hypertensive, and 105 (41.5%) were obese. A family history of breast cancer was found in 21 patients (8.3%), while 8 patients (3.16%) had a family history of endometrial cancer. Four patients (1.91%) had a personal history of breast cancer surgery. The mean gravidity was 6.58 (range: 0–14), and the mean parity was 5.23 (range: 0–13). Multiparity was predominant, with 145 patients (69.37%). The mean age at menopause was 49.3 years (range: 37–59). Two patients had early menopause (at 37 and 39 years), while 13 patients (5.13%) had late menopause (\geq 55 years). The mean duration of menopause at the onset of bleeding was 8.42 years (range: 2–37). Four patients had received HRT, and none developed endometrial cancer.

Gynecological examination was normal in 158 patients (62.45%) and abnormal in 95 (37.54%), revealing: 36 cases of cervical polyps, 18 cases of associated urogenital prolapse, 19 enlarged uteri, 14 exocervicitis, 5 abdominopelvic masses, 1 case of indurated ulcerated cervix (suspicious), and 2 vaginal tumorous lesions.

In our series, 167 patients (66%) had a normal uterine size on ultrasound with regular contours and homogeneous echotexture. Conversely, 41 patients (16.2%) had an enlarged uterus. In 45 patients, uterine size was not specified. Ultrasound revealed intracavitary images (polyps, submucosal fibroids) in 25 patients (9.88%) and uterine fibroids in 52 patients (20.55%). Benign-appearing ovarian cysts were

observed in 22 cases, and one case of a poorly defined heterogeneous ovarian mass suggestive of malignancy was identified.

The mean endometrial thickness was 7.17 mm (range: 0.6–37 mm). In 18 cases, endometrial thickness was not reported. Using a 4 mm threshold, a thickened endometrium was noted in 157 patients (62.05%) (Figure 1).



Hysteroscopy was performed in 232 patients; however, reports were available for only 227 of them. Hysteroscopy revealed an isolated atrophic appearance of the uterine mucosa in 102 patients (44.93% of cases), representing the most frequent hysteroscopic finding (**Table 1**).

In 13 patients, atrophy was associated with an endometrial polyp; in 2 patients with a fibroid; in 2 patients with a budding lesion; and in 1 patient with localized hypertrophy.

An endometrial polyp was diagnosed by hysteroscopy in 42 patients (18.5% of cases), including 13 polyps associated with endometrial atrophy, 9 associated with endometrial hypertrophy, 1 associated with a budding lesion, and 19 isolated polyps.

Isolated hypertrophy was observed in 25 patients (11.01% of cases). Hypertrophy associated with fibroid was found in 2 patients, hypertrophy associated with intrauterine synechiae in 3 patients, and hypertrophy associated with a budding endometrial lesion in 1 patient. An isolated budding endometrial lesion was observed in 6 patients, whereas in 12 patients, hysteroscopy did not reveal any abnormality of the uterine cavity. The results of uterine cavity exploration by hysteroscopy are summarized in Table 1.

A hysteroscopic procedure was performed in all 227 patients who underwent diagnostic hysteroscopy. In 4 patients presenting with complete cervical synechiae, hysteroscopic access was not possible. A curettage with endometrial biopsy was performed in 208 patients, and operative hysteroscopy was carried out in 15 cases.

The histological results of the endometrial biopsies are summarized in Table 2. Isolated endometrial hyperplasia was observed in 36 patients, including 20 cases of simple hyperplasia without atypia and 16 cases of complex hyperplasia with atypia.

The 16 patients with complex hyperplasia and atypia underwent total hysterectomy with bilateral adnexectomy. Histopathological examination revealed adenocarcinoma (ADK) in 14 of these patients, while 2 showed no evidence of carcinomatous transformation.

Endometrial cancer was diagnosed in 21 patients based on histological examination of endometrial biopsies.

Table 1: Appearance of the Uterine Cavity on Hysteroscopy

HYSTEROSCOPIC APPEARANCE	NUMBER OF CASES	PERCENTAGE (%)
ISOLATED ATROPHY	102	44.93
ISOLATED HYPERTROPHY	25	11.01
ATROPHY + LOCALIZED HYPERTROPHY	1	0.44
ISOLATED POLYP	19	8.37
ATROPHY + POLYP	13	5.72
ATROPHY + FIBROID	3	1.32
HYPERTROPHY + POLYP	9	3.96
HYPERTROPHY + FIBROID	2	1.05
HYPERTROPHY + SYNECHIAE	3	1.32
ISOLATED FIBROID	13	5.72
ISOLATED SYNECHIAE	10	4.44
ISOLATED BUDDING LESION	6	2.61
BUDDING LESION + ATROPHY	2	0.88
BUDDING LESION + POLYP	1	0.44
BUDDING LESION + HYPERTROPHY	1	0.44
ENDOMETRITIS	1	0.44
NO ABNORMALITIES	12	5.28
NOT EXPLORED (COMPLETE CERVICAL SYNECHIAE)	4	1.76
TOTAL	227	100

Table 2: Histological Results of Endometrial Biopsies

HISTOLOGICAL DIAGNOSIS	NUMBER OF CASES	PERCENTAGE (%)
ENDOMETRIAL ATROPHY	40	19.04
ISOLATED HYPERPLASIA	36	17.14
ISOLATED POLYP	46	21.95
ISOLATED FIBROID	10	4.76
POLYP + FIBROID	4	1.90
ENDOMETRIAL CARCINOMA	21	9.95
POLYP + SIMPLE HYPERPLASIA	4	1.90
POLYP + CHRONIC ENDOMETRITIS + ADENOMYOSIS	4	1.90
NO ABNORMALITY DETECTED	33	15.64
NON-DIAGNOSTIC SPECIMEN	10	4.73
REPORT UNAVAILABLE	3	1.42
TOTAL	211	100

The histological results concerning endometrial cancer, obtained either from biopsy or from the pathological examination of the surgical specimen, using a 4 mm threshold value for endometrial thickness, are summarized in Table 3.

We found a higher percentage of malignant tumors in the group with an endometrial thickness > 4 mm (13.37%) compared to the group with a thickness ≤ 4 mm. This difference was statistically significant (Chi-square test), *P* = 0.0025.

Table 3: Correlation Between Endometrial Thickness (Threshold Value: 4 mm) and Histological Results

ENDOMETRIAL THICKNESS (ULTRASOUND)	NUMBER OF PATIENTS	ENDOMETRIAL CANCER (N)
≤ 4 MM	78	0
> 4 MM	157	21

We studied the sensitivity, specificity, positive predictive value (PPV), and negative predictive value (NPV) of transvaginal ultrasound (TVUS) in detecting endometrial pathology. These parameters were calculated for the 253 patients who underwent ultrasound examination.

The sensitivity of TVUS in detecting endometrial pathology was 87.52%, with a specificity of 75%, a PPV of 89.25%, and a NPV of 54%.

We also evaluated the diagnostic performance of TVUS in detecting malignant tumors in cases of postmenopausal bleeding (PMB) among the 235 patients who had a measurement of endometrial thickness. For a threshold value of 4 mm, the sensitivity of TVUS in diagnosing endometrial cancer was 100%, with a specificity of 25.34%, a PPV of 23.48%, and a NPV of 100%.

Furthermore, we assessed the performance of ultrasound in detecting endometrial atrophy, hyperplasia, polyps, and uterine fibroids.

The sensitivity of TVUS in diagnosing endometrial atrophy was 100%, with a specificity of 71.23%, a NPV of 83.65%, and a PPV of 49.54%.

For endometrial hyperplasia, the sensitivity of ultrasound was 96.35%, with a specificity of 53.66%, a PPV of 40.52%, and an NPV of 94.75%.

In the case of endometrial polyps, we found a sensitivity of 92.73%, a specificity of 97.68%, a PPV of 80.62%, and an NPV of 80.62%.

The sensitivity of ultrasound in detecting uterine fibroids was 80.23%, with a specificity of 84.31%, a PPV of 42.35%, and an NPV of 95.23%.

Discussion

In the literature, the sensitivity, specificity, and positive predictive value (PPV) of transvaginal ultrasound (TVUS) for diagnosing endometrial pathology in cases of postmenopausal bleeding (PMB) have been extensively studied.

According to Matarbacha et al. [3], the sensitivity of ultrasound is 76.34%, with a specificity of 25% in the etiological diagnosis of PMB. Similarly, a study conducted in 2011 by Bingol B et al. [4] reported a sensitivity of 70%, a specificity of 50%, and a PPV of 80.9%.

In our study, for the diagnosis of endometrial pathologies, ultrasound demonstrated a sensitivity of 87.52%, a specificity of 75%, and a PPV of 89.25%. Thus, TVUS represents a reliable first-line diagnostic

tool, allowing exclusion of endometrial abnormalities in cases of PMB when the endometrium is thin and no anomalies are detected. It can reduce invasive investigations by approximately 40% [5].

However, the sensitivity and specificity of ultrasound vary according to the underlying etiology (Table 5). In our study, the sensitivity of TVUS for detecting endometrial polyps did not correspond fully with previously reported results in the literature.

In patients presenting with PMB who are at high risk of endometrial cancer, TVUS is the first proposed examination [9]. Several studies highlight the usefulness of measuring endometrial thickness in determining endometrial pathology, but the debate regarding the threshold value and the contribution of TVUS in diagnosing endometrial cancer remains ongoing (Table 4).

Table 4: Sensitivity, Specificity, PPV, and NPV of Transvaginal Ultrasound (TVUS) According to Etiology

AUTHORS	YEAR	NUMBER OF CASES	ETIOLOGIES	SENSITIVITY (%)	SPECIFICITY (%)	PPV (%)	NPV (%)
KEBAILI S. ET AL. [6]	2009	92	Atrophy, Hypertrophy, Fibroid, Polyp	51.8, 93.7, 75, 26.8	75.6, 45.8, 72, 73.6	60.8, 36.5, -, -	68.5, 95.6, 96.8, -
BINGOL B. ET AL. [4]	2011	137	Atrophy, Hypertrophy, Fibroid, Polyp	100, 69.2, 65, 55.7	97.5, 80.6, 84.7, 85	85, 58.7, 69, 81.2	100, 68.6, 75.7, 70.8
VALENTIN L. [7]	2014	6000	Fibroid, Polyp	49, 33	81, 97	-, -	-, -
MATARBACH R. ET AL. [8]	2015	205	Atrophy, Hypertrophy, Fibroid, Polyp	50, 95.45, 50, 4	77.31, 47.76, 89.47, 96	56.4, 5, 37.5, 33.3, 3, 25	72.4, 4, 96.9, 6, 94.4, 4, 76.2, 3
OUR STUDY	2024	253	Atrophy, Hypertrophy, Fibroid, Polyp	100, 96.35, 80.23, 92.73	71.23, 53.66, 84.31, 97.68	49.5, 1, 40.5, 2, 42.3, 5, 32.3, 4	83.6, 5, 94.7, 5, 95.2, 3, 80.6, 2

Roger V et al. [10] found in their study that, using a 5 mm threshold for endometrial thickness, the sensitivity of TVUS in detecting endometrial cancer was 100%, with a specificity of 96% and a positive predictive value (PPV) of 87.3%.

In the study by Williams SC et al. [11], which included 277 patients evaluated for PMB, the malignancy rate was 7.2% in patients with a thickened endometrium.

Van Hanegem N et al. [12] and Timmermans A et al. [13] recommend a threshold of 3 mm, reporting a sensitivity of 98% and a specificity of 35%.

Some authors suggest that a 4 mm threshold excludes endometrial cancer in most cases [14,15], and that biopsy is only necessary if the endometrial thickness exceeds 4 mm or if there is focal thickening. They note that nearly 80% of biopsies reveal benign pathology [15].

Smith PP et al. [16] report that the prevalence of malignancy is reduced to less than 1% when the endometrial thickness is ≤ 4 mm. However, Tsikouras P et al. [17] report a malignancy prevalence of 8.6% with the same threshold.

According to Okaro E [18], using a threshold greater than 4 mm to define an abnormal endometrium allows detection of 96% of women with endometrial cancer and 92% of women with endometrial pathology (hyperplasia, polyp), with false positive rates of 39% and 19%, respectively.

Garuti G et al. [19] found cancer rates of 0.24% for endometrial thickness ≤ 4 mm, 1.9% for 4–8 mm, and 12% for > 8 mm.

However, several authors have reported cases of endometrial cancer with a thickness ≤ 4 mm (ranging from 2 to 4 mm). For these authors, hysteroscopy remains essential, even in the absence of thickening on ultrasound. Smith-Bindman R et al. [20] recommend a 5 mm threshold for screening malignant lesions.

Bezircioglu I et al. [21] report that the sensitivity of TVUS for detecting cancers with a 5 mm threshold is 94.4%, with a specificity of 44.2%, and that 26.3% of cancers occur in patients with thickness > 5 mm.

Bruchim I et al. [22] found no cancers for endometrial thickness ≤ 5 mm, noted a 10% cancer rate for thickness between 5 and 9 mm, and 18% for thickness > 9 mm.

In our study, among patients with endometrial cancer, thickness ranged from 5 to 38 mm, with a cancer rate of 9.56%.

Smith-Bindman R et al. [20] and Tabor A et al. [23] observed that a 4–5 mm threshold could miss 1–4% of cancers. This relatively high rate does not reduce the need for invasive investigations to rule out malignant causes.

Malinova M and Pehlivanov B [24] demonstrated in a prospective study correlating endometrial thickness and histology that TVUS had a sensitivity of 100% and a specificity of 64% for a 6 mm threshold. All endometrial cancers were found in patients with thickness > 7 mm, leading these authors to perform biopsy only for patients with thickness ≥ 6 mm.

However, Dorum A et al. [25] argue that endometrial thickness alone is insufficient to exclude pathology. They conclude that ultrasound cannot replace histological examination in the evaluation of PMB.

In patients on hormone replacement therapy (HRT), endometrial thickness varies depending on progestogen use [26]. Continuous combined therapy produces a thin, hypotrophic endometrium on TVUS, while cyclic combined therapy results in thickness variation according to the cycle phase, with the thinnest measurement immediately after stopping progestogen.

The risk of endometrial cancer in women on cyclic combined HRT is 0.2% for endometrial thickness ≤ 5 mm [26]. Crum CP et al. [27] recommend an 8 mm threshold for women on HRT, despite its low

specificity. Munro MG et al. [26] suggest that thresholds for women not on HRT can be applied to women on HRT, but with a high false-positive rate.

Measurement of endometrial thickness in asymptomatic postmenopausal women is also controversial. A 4 mm threshold has been supported by some authors [20,27]. However, using this threshold as abnormal would likely generate many false positives. Higher thresholds are still under discussion [26]. Other authors proposed 8 mm as abnormal in asymptomatic postmenopausal women, but Smith-Bindman R et al. observed that this would result in biopsies in 1% of “normal” postmenopausal women [20].

Brooks SE et al. [28] studied 129 asymptomatic postmenopausal women with thickened endometrium on TVUS. No cases of endometrial cancer were reported. In 23 patients, the thickness was due to fluid accumulation.

Conclusion

Given its performance and simplicity, TVUS represents a first-line screening examination in the evaluation of PMB. Due to variable sensitivity and specificity depending on etiology, it should be coupled with hysteroscopy and endometrial biopsy when endometrial thickness exceeds 4 mm and/or anomalies are present. For thickness ≤ 4 mm and in the absence of anomalies, TVUS alone is sufficient, and expectant management is appropriate.

Références:

1. **Singh S, Best C, Dunn S, Leyland N, Wolfman WL.** Saignements utérins anormaux chez les femmes préménopausées. *J ObstetGynaecol Can.* 2013;35 suppl1:S1-S32.
2. **Hsu CY, Chen CP, Wang KL.** Assessment of postmenopausal bleeding. *Int J Gerontol.* 2008;2(2):55-9.
3. **Matarbacha E, Persson I, Adami HO, Magnusson C, Lindgren A, Baron JA.** Body size in different periods of life, diabetes mellitus, hypertension, and risk of postmenopausal endometrial cancer (Sweden). *Cancer Causes Control.* 2000;11(2):185-92.
4. **Bingol B, Gunenc MZ, Gedikbasi A, Guner H, Tasdemir S, Tiras B.** Comparison of diagnostic accuracy of saline infusion sonohysterography, Transvaginal sonography and hysteroscopy in postmenopausal bleeding. *Arch GynecolObstet.* 2011; 284(1):111-7.
5. **Ahmadi S.** Apport de l'échographie endovaginale et de l'hystérocopie dans l'exploration des métrorragies post-ménopausiques [Thèse]. Médecine: Sousse; 2000. 87p.
6. **Kebaili S, Ben Ayed B, Chahtour H, Mathlouthi N, Dhuib M, Dammak S, et al.** L'exploration des métrorragies post ménopausiques (MPM). Corrélation échographie endovaginale-histologie : à propos de 82 cas. *J Femme.* 2009;19(2):129-35.
7. **Valentin L.** Imaging techniques in the management of abnormal vaginal bleeding in non-pregnant women before and after menopause. *Best PractRes Clin ObstetGynaecol.* 2014;28(5):637-54 .
8. **Materbacha R, Bouguerra B, Rammeh S, Elfekih C.** Métrorragies post ménopausiques : corrélation de la mesure échographique à l'étude histologique 2015 ;42(3) :101-42
9. **Towbin NA, Gviazda IM, March CM.** Office hysteroscopy versus transvaginal ultrasonography in the evaluation of patients with excessive uterine bleeding. *Am J Obstet Gynecol.* 1996; 174(6):1678-82.
10. **Roger V, Jemal A, Siegel R, Ward E, Hao Y, Xu J, Murray T, et al.** Cancer statistics, 2008. *CA Cancer J Clin.* 2008;58(2):71-96.

11. **Muriel Viala-Trentinia , Antoine Maubonb, Jean-Pierre Rouaneta .** IRM de l'endomètre avant les résultats de l'histologie : du bilan d'un cancer à la gestion des incidentalomes ; Imagerie de la Femme .2009 ; 19 :155-162.
12. **Van Hanegem N, Breijer MC, Khan KS, Clark TJ, Burger MP, Mol BW, et al.** Diagnostic evaluation of the endometrium in postmenopausal bleeding: an evidence-based approach. *Maturitas*. 2011; 68(2):155-64.
13. **Sahdev A.** Imaging appearances with histopathological correlation in adenocarcinomas of the cervix.RSNA. 2006, LL-OB3201.
14. **Lécuru F, Ansquer Y, Bats AS, Olschwang S, Laurent-Puig P, Eisinger F.** Cancer de l'endomètre du syndrome HNPCC : Actualisation des données. *J GynecolObst et Biol Reprod*. 2008;37(6):547-53.
15. **Clark TJ, Voit D, Gupta JK, Hyde C, Song F, Khan KS.** Accuracy of hysteroscopy in the diagnosis of endometrial cancer and hyperplasia: a systematic quantitative review. *JAMA*. 2002;288(13):1610-21.
16. **Smith PP, O'Connor S, Gupta J, Clark TJ.** Recurrent postmenopausal bleeding: a prospective cohort study. *J Minim Invasive Gynecol*. 2014;21(5):799-803.
17. **Tsikouras P, Liberis V, Galazios G, Grapsas X, Kantari P, Papageorgiou S, et al.** TV sonographic assessment in postmenopausal women with bleeding. *Eur J Gynaecol Oncol*. 2008; 29(1):67-71.
18. **Okaro E, Bourne T.** Sporadic abnormal vaginal bleeding (intermenstrual, postcoital and postmenopausal bleeding). *CurrObstetGynecol*. 2002; 12(6):334-40.
19. **Garuti G, Cellani F, Garzia D, Colonnelli M, Luerti M.** Accuracy of hysteroscopic diagnosis of endometrial hyperplasia: a retrospective study of 323 patients. *J Minim Invasive Gynecol*. 2005; 12(3):247-53.
20. **Smith-Bindman R, Kerlikowske K, Feldstein VA, Subak L, Scheidler J, Segal M, et al.** Endovaginal ultrasound to exclude endometrial cancer and other endometrial abnormalities. *JAMA*. 1998; 280(17):1510-7.
21. **Bezircioglu I, Baloglu A, Cetinkaya B, Yigit S, Oziz E.** The diagnostic value of the Doppler ultrasonography in distinguishing the endometrial malignancies in women with postmenopausal bleeding. *Arch GynecolObstet*. 2012; 285(5):1369-74.
22. **Bruchim I, Biron-Shental T, Altaras MM, Fishman A, Beyth Y, Tepper R, et al.** Combination of endometrial thickness and time since menopause in predicting endometrial cancer in women with postmenopausal bleeding. *J clin ultrasound*. 2004; 32(5):219-24.
23. **Tabor A, Watt HC, Wald NJ.** Endometrial thickness as a test for endometrial cancer in women with postmenopausal vaginal bleeding. *ObstetGynecol*. 2002;99(4):663-70.
24. **Malinova M, Pehlivanov B.** Transvaginal sonography and endometrial thickness in patients with postmenopausal uterine bleeding. *Eur J ObstetGynecolReprod Biol*. 1995;58(2):161-5.
25. **Dorum A, Kristensen GB, Langebrekke A, Sornes T, Skaar O.** Evaluation of endometrial thickness measured by endovaginal ultrasound in women with postmenopausal bleeding. *Acta ObstetGynecolScand*. 1993;72(2):116-9.

26. **Munro MG, Southern California Permanente Medical Group's Abnormal Uterine Bleeding Working G.** Investigation of women with postmenopausal uterine bleeding: clinical practice recommendations. *Perm J.* 2014;18(1):55-70.
27. **Crum CP, Duska LR, Nucci MR.** Adenocarcinoma, Carcinosarcoma and Other Epithelial Tumors of the Endometrium. *Diagnostic Gynecologic and Obstetric Pathology*, 2nd Edition. Boston: Saunders Elsevier. 2011; p. 517-81..
28. **Brooks SE, Yeatts-Peterson M, Baker SP, Reuter KL.** Thickened endometrial stripe and/or endometrial fluid as a marker of pathology: fact or fancy? *GynecolOncol.* 1996;63(1):19-24.