

Prospective Observational Study of Treatment of Lateral End Clavicle Fracture (Type 2b, Neer Classification) with Coracoclavicular Endobutton and Fiber Tap Technique

Dr. Kushagra S Dave¹, Dr. Parth P Thakor²

¹3rd Year PG Resident, Orthopaedics, Zydus Medical College and Hospital

²Associate Professor, Orthopaedic, Zydus Medical College and Hospital

Abstract

A prospective study comprising of 20 patients, admitted and treated at a tertiary care hospital Zydus Medical College and Hospital Dahod, having type 2b lateral end clavicular fractures and treated with the endobutton technique, with the aim to evaluate the results and with objective of analyzing the functional outcome of the endobutton technique as a treatment modality for the lateral end clavicle fractures. The patients were regularly followed up at 6 months, 12 months and 18 months post-operatively, with good results and patient having stable painless and properly mobile shoulder and acromioclavicular joint with the help of proper and regular follow up, rehabilitation and adequate physiotherapy. UCLA score was used to evaluate the patients post-operatively to assess the condition of the patient and the impact the surgical technique has had on the quality of life of the patient.

Keywords: Lateral end clavicle, endobutton, UCLA score

Introduction

The clavicle fractures are relatively common injuries because of their subcutaneous position and constitute for about 2-4 percent of adult fractures(1). Of these lateral end clavicle fractures account for 12-15%(2). Neer divided fractures into 3 types depending upon relationship of fracture line with coracoclavicular and acromioclavicular ligaments(3). Fractures with complete displacement are less common but have a higher risk of subsequent non union(1,3,4,5,6). Persistent pain, restriction of movement and loss of strength and endurance of shoulder may develop if the fracture fails to heal(7,8). Coracoclavicular loops and slings of synthetic materials, allograft and autograft are less rigid and have been used in the treatment of acromioclavicular separations(9). However, the use of these techniques in the treatment of displaced lateral clavicular fractures is less well defined(10,11,12,13,14)

Aim: Achieve goal of modern orthopedics: Complete functional recovery, early mobilization, Minimally invasive surgery and evidence based decision making for lateral end clavicle (Type 3, Neer classification)


Objective: Careful selection of patient preoperatively To operate all selected patients by standardized technique of Coracoclavicular Endobutton and fiber tap technique Post-operative evaluation of patient up to one year, comparison of results with other series and other techniques

Material and methods: Prospective, non-competitive, result oriented, observational studies To be carried out at 1000 bed tertiary care hospital: Zydus Medical college and Hospital – Dahod Patient inclusion criteria: Patients with lateral end clavicle fracture (Type 2b , Neer classification) treated at hospital between May 2024 to March 2026

Sample size: Minimum 20 patients

Evaluation: Periodic evaluation of results (Radiological and clinical) for 1 year post operatively at minimum 3 months interval. Functional evaluation by UCLA score

Identity of patients will be kept confidential and study would be conducted after permission and under vigilance of Ethics committee



Surgical technique

All patients underwent the same ORIF procedure using the continuous loop double endobutton technique.

Deltoid splitting incision was used

Deltotrapezial fascia was incised

Fracture fully exposed and anatomically reduced

2.4 mm drill hole in top of clavicle

Reamed over with a 4.5 mm cannulated reamer

2nd drill hole 1 cm lateral to central drill hole

Loop length determined, which comes in 5 mm increments

Measured length less than 1 mm of standard loop size – next larger size used

If within 1 mm of the standard loop size- regular endobutton was used

Polyethylene suture used, with joint held in reduction, loop is tied securing the button

Trapezoid stich was taken

After reconstruction, fracture site reduction and apposition is the main priority

Post operative treatment

Sling for 4 weeks

Passive external rotation and shoulder exercises started at 2 weeks

Discontinue sling after 4 weeks

Active movement of shoulder encouraged

Outcome assessment

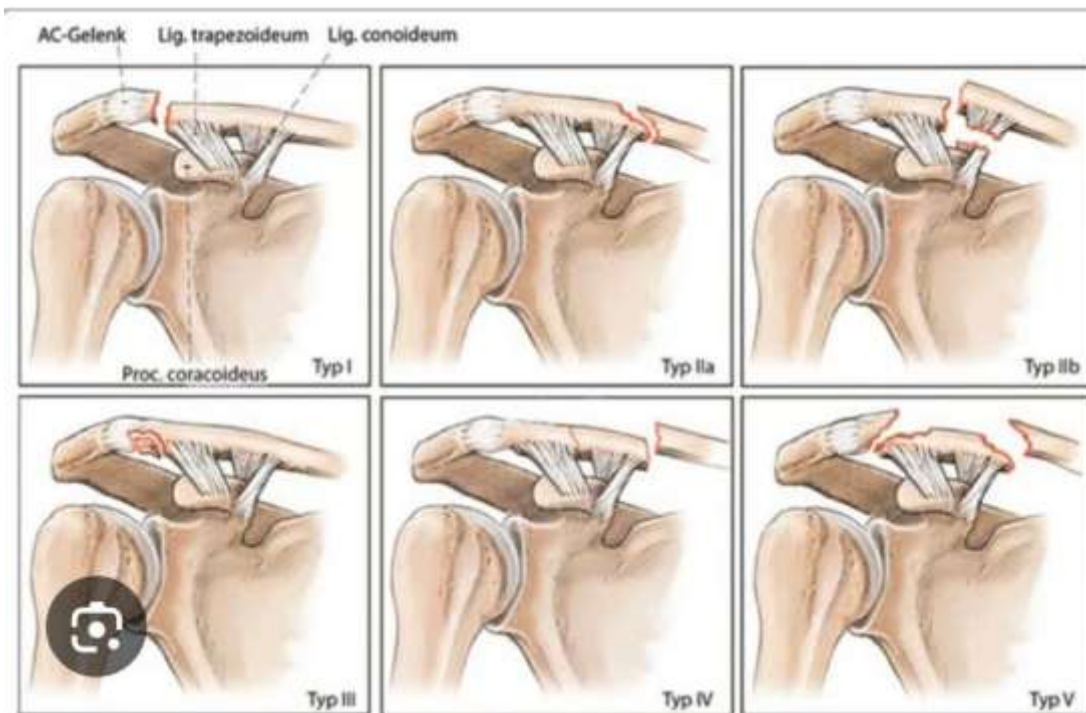
The chief criteria were clinical follow up, radiological outcome and fracture related complications

The patients were evaluated at 0, 6, 12 and 18 months

The data regarding patient returning back to normal daily work, range of movements of shoulder, tested for weakness of rotator cuff, impingement lesions, signs of dysfunction at the AC joint.

We considered fractures united if patient had no pain or only mild activity related discomfort and there were no radiological signs of loss of reduction, implant loosening or breakage, or resorption at the fracture site.

Neer classification



UCLA score

UCLA Shoulder rating scale

Clinician's Name: _____ Patient's Name: _____

Section 1 - Pain

- Present always and unbearable; strong medication frequently
- Present always but bearable; strong medication occasionally
- None or little at rest; present during light activities; salicylates used frequently
- Present during heavy or particular activities only; salicylates used occasionally
- Occasional and slight
- None

Section 2 - Function

- Unable to use limb
- Only light activities possible
- Able to do light housework or most activities of daily living
- Most housework, shopping, and driving possible; able to do hair and to dress and undress, including fastening bra
- Slight restriction only; able to work above shoulder level
- Normal activities

Section 3 - Active forward flexion

- 150°
- 120°-150°
- 90°-120°
- 45°-90°
- 30°-45°
- <30°

Section 4 - Strength of forward flexion (manual muscle testing)

- Grade 5 (normal)
- Grade 4 (good)
- Grade 3 (fair)
- Grade 2 (poor)
- Grade 1 (muscle concentration)
- Grade 0 (nothing)

Section 5 - Satisfaction of patient

- Satisfied and better
- Not satisfied and worse

Total UCLA Shoulder score is: 0

Modified UCLA score

Patient satisfaction

- 0 Patient feels procedure was not successful
- 5 Patient feels procedure was a success

Active forward flexion range of motion

- 0 Less than 30°
- 1 30°-45°
- 2 45°-90°
- 3 90°-120°
- 4 120°-150°
- 5 Greater than 150°

Strength of forward flexion

- 0 No active contraction
- 1 Evidence of slight muscle contraction, no active elevation
- 2 Complete active forward flexion with gravity eliminated
- 3 Complete active forward flexion against gravity
- 4 Complete active forward flexion against gravity with some resistance
- 5 Complete active forward flexion against gravity with full resistance

Pain

- 1 Present always and unbearable, strong medication frequently
- 2 Present always but bearable, strong medication occasionally
- 4 None or little at rest, present during light activities; salicylates frequently
- 6 Present during heavy or particular activities only, salicylates occasionally
- 8 Occasional and slight
- 10 None

Function

- 1 Unable to use limb
- 2 Only light activities possible
- 3 Able to do light housework or most activities of daily living
- 6 Most housework, shopping, and driving possible; able to do hair and to dress and undress, including fastening brassiere
- 8 Slight restriction only, able to work above shoulder level
- 10 Normal activities

Total

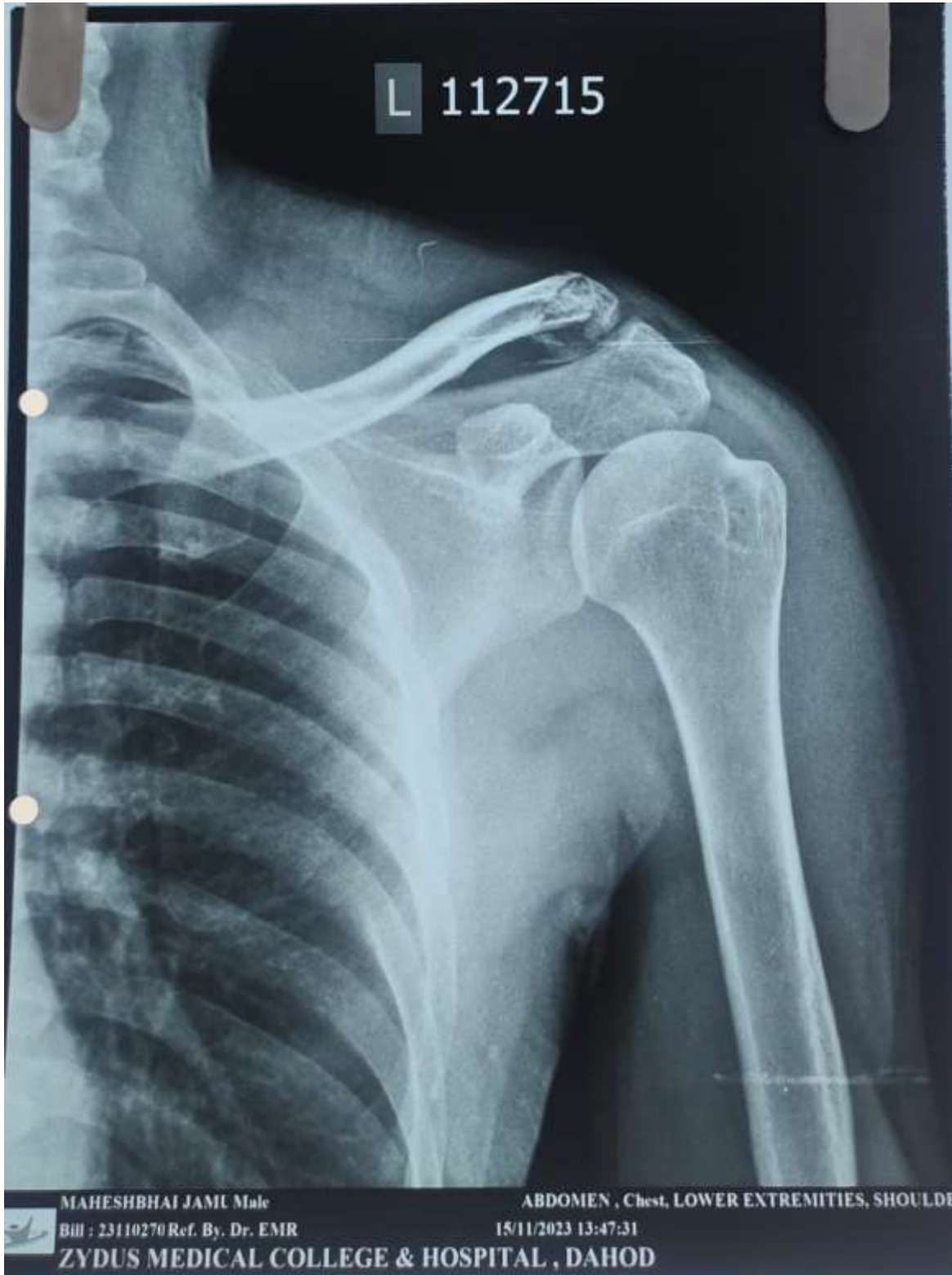- Excellent: 34-35
- Good: 28-33
- Fair: 21-27
- Poor: 0-20

Follow up

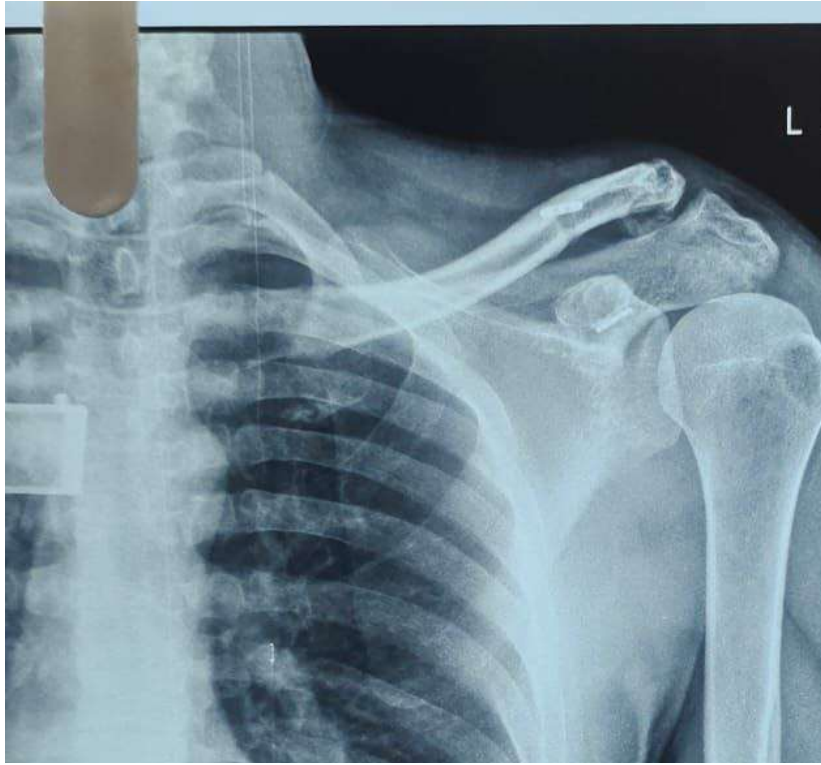
A 25 year old male patient with type 2b neer classification left side closed displaced lateral end clavicular fracture without distal neurovascular deficit, was treated with the surgical technique of endobutton with loop

The patient was followed up post operatively for 6 months , 12 months and 18 months

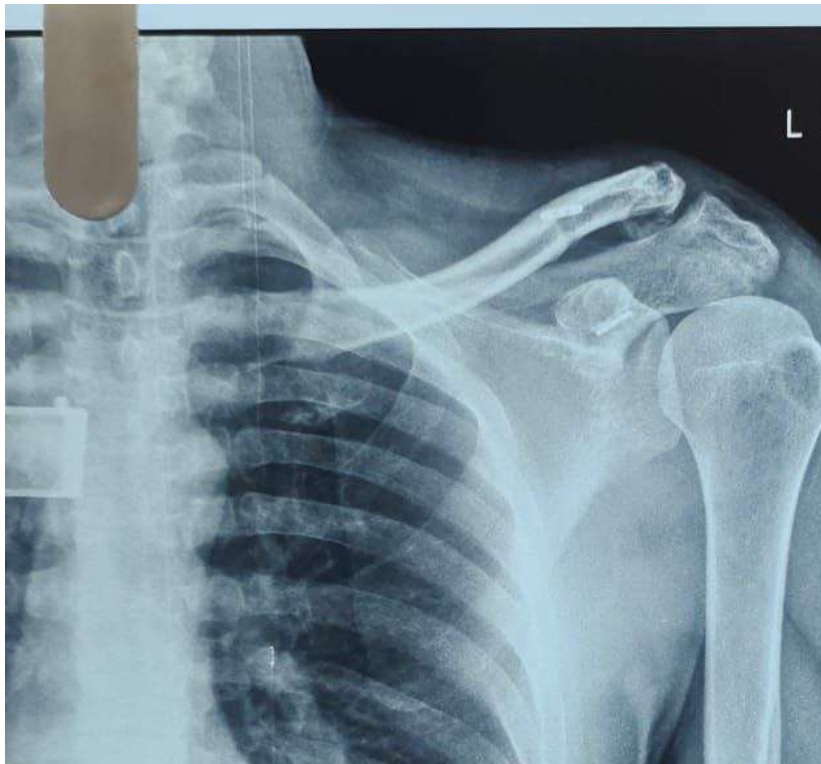
Pre operative x ray



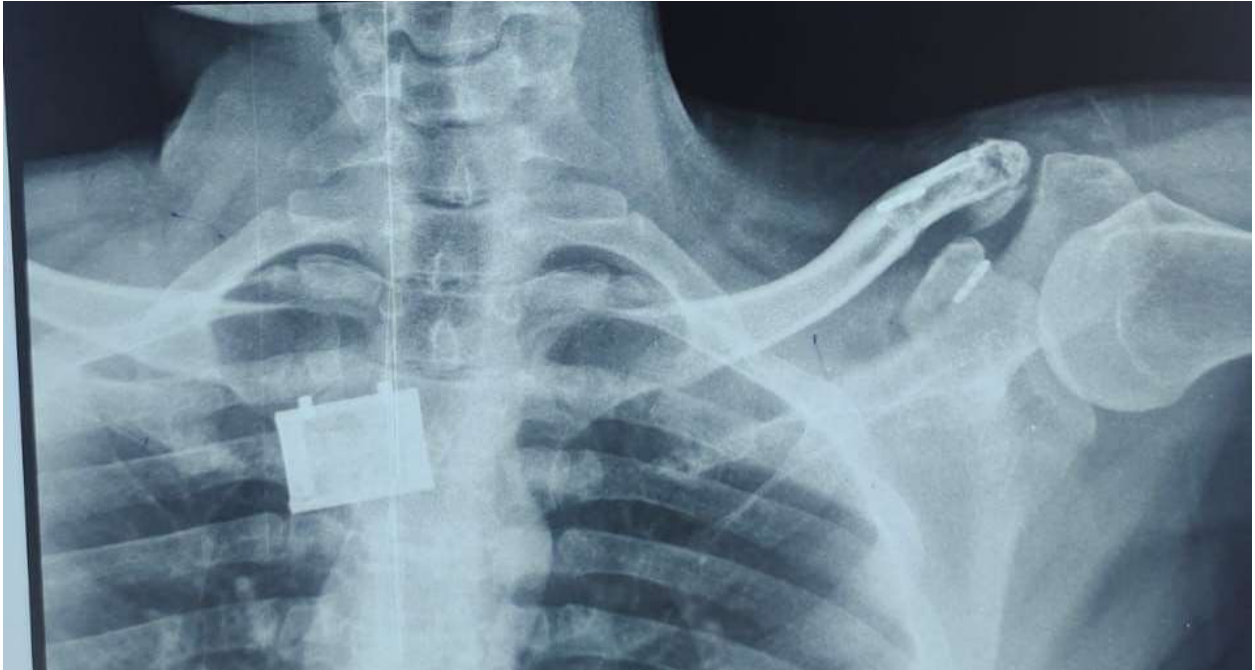
Immediate post operative xray



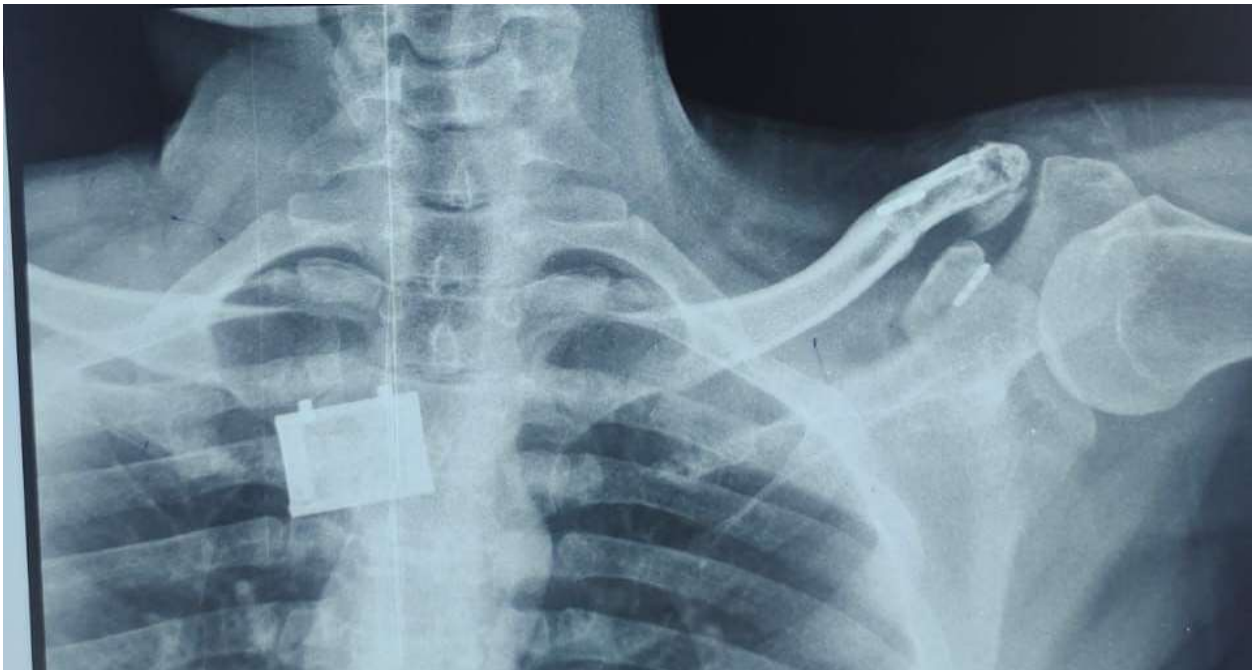
6 months follow up



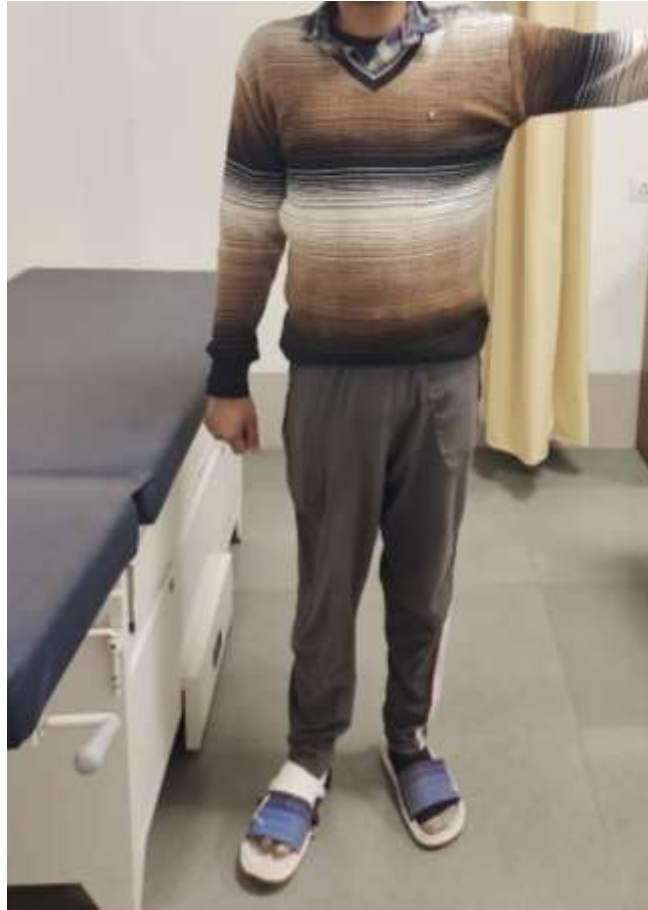
12 month follow up

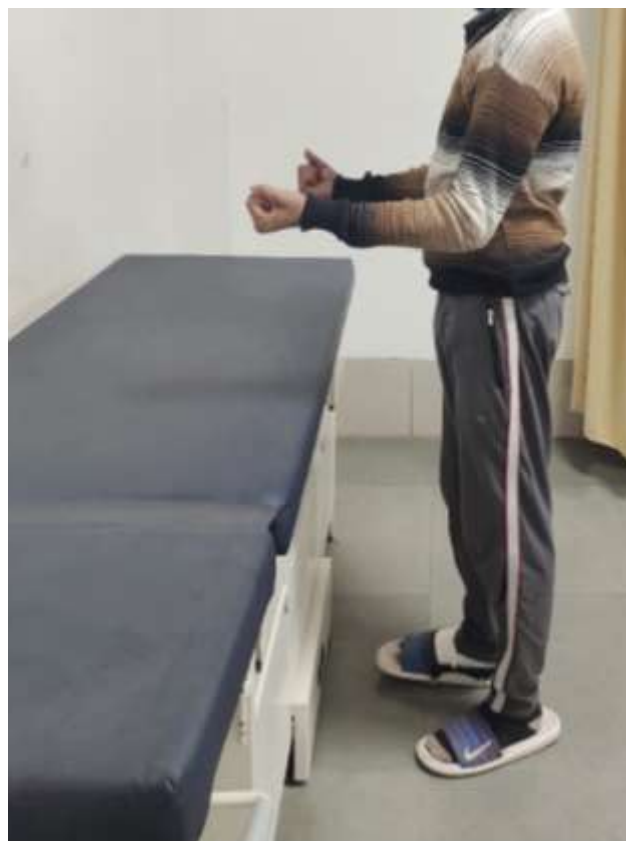

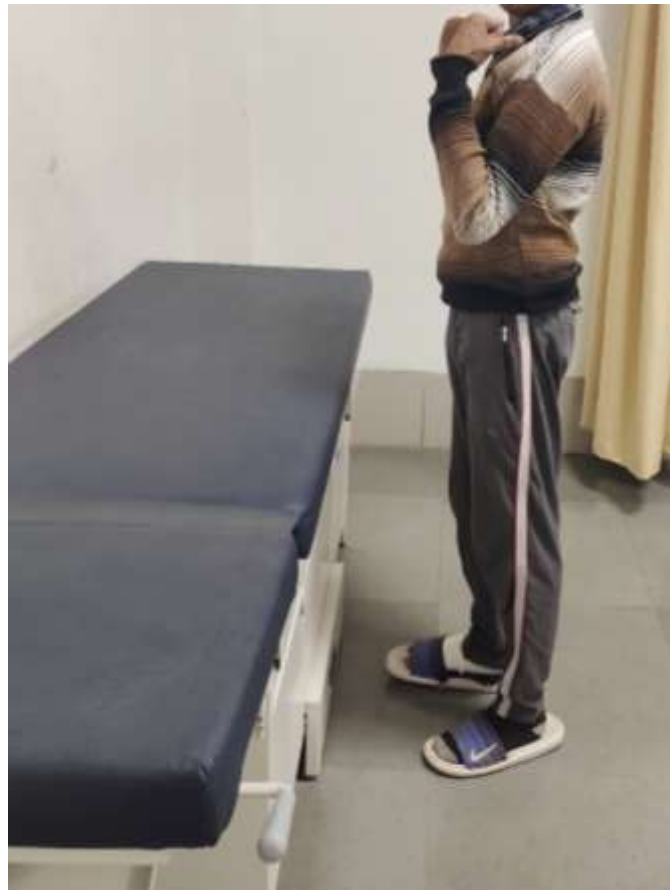18 month follow up



Clinical images







Results

All patients show radiological union with good to excellent outcome
Post operative follow up at 6, 12, 18 months

Discussion

Operative intervention the majority look at mid shaft clavicle fractures
The endobutton technique was initially developed for reduction of ankle syndesmosis but has been adopted by upper limb surgeons and is now a recognized means of correction. It results in better cosmetic appearance, better patient reported outcomes

Conclusion

The study shows encouraging prospect in purely biological osteosynthesis with functional outcome at par with other methods of fixation while avoiding implant related complications Compliance with ethical standards All procedures performed in studies involving human participants were in accordance with the ethical standards. Informed consent was obtained from all individuals participating in the study

References

1. Robinson CM: fractures of clavicle in the adult. Epidemiology and classification. J Bone Joint Surg Br.1998
2. Ballmer FT, Gerber C: coracoclavicular screw fixation for unstable fractures of the distal clavicle. A report of five cases. J Bone Joint Surg Br. 1991

3. Neer CS 2nd : Fractures of the distal third of the clavicle. Clin Orthop Relat Res. 1968
4. Nordquist A, Peterson C, Redlund- Johnell I The natural course of lateral clavicle fractures: 15(11-21) year follow up of 100 cases. Acta Orthop Scand 1993
5. Edwards DJ, Kvanagh TG, Flannery MC. Fractures of the distal clavicle: a case of fixation of . Injury 1992
6. Kavanagh TG, Sarkar SD. Complications of displaced fractures of outer end of the clavicle. J Bone Joint Surg(Br) 1985
7. Eskola A, Vainionpaa S, Patiala H, Rokkanen P. Outcome of operative treatment in fresh lateral clavicular fracture. Ann Chir Gynaecol 1987
8. Jupiter JB, Leffert RD. Non union of the clavicle: associated complications and surgical management. J Bone Joint Surg (Am) 1987
9. Fraser- Moodie JA, Shortt NL, Robinson CM. Injuries to the acromioclavicular joint. J Bone Joint Surg (Br) 2008
10. Hessmann M, Kirchner R , Baumgaertel F, Gehling H, Gotzen L. Treatment of unstable distal clavicular fractures with and without lesions of the acromioclavicular joint. Injury 1996
11. Goldberg JA, Bruce WJ, Sonnabend DH, Walsh WR. Type 2 fractures of the distal clavicle: a new surgical technique. J Shoulder Elbow Surg 1997
12. Levy O. Simple, minimally invasive surgical technique for treatment of type 2 fractures of the distal clavicle. J shoulder Elbow Surg 2003
13. Webber MC, Haines JF. The treatment of lateral clavicle fractures. Injury 2000
14. Shin S, Roh KJ, Kim JO, Sohn HS. Treatment of unstable distal clavicle fractures using two suture anchors and suture tension bands. Injury 2009