International Journal for Multidisciplinary Research (IJFMR)
E-ISSN: 2582-2160 ● Website: www.ijfmr.com ● Email: editor@ijfmr.com

Clinical and Therapeutic Profiles of Post-Traumatic Arteriovenous Fistulas: A Retrospective Series of 21 Cases

Dr. Meryem Sassi[1], Prof. Hamza Naouli[2], Prof. Samir El Youbi[3], Prof. Jiber Hamid[4], Prof. Bouarhroum Abdellatif[5]

[1,2,3,4,5]Vascular Surgery Departement, Uhc Hassan II

Abstract

Introduction: Post-traumatic arteriovenous fistulas (PTAVFs) are rare clinical and pathological entities in civilian practice. Often overlooked during the acute phase, the diagnosis and management of PTAVFs represent a significant challenge for vascular surgeons.

Materials and Methods: We report our experience regarding the diagnostic and therapeutic modalities of limb PTAVFs through a retrospective series of 21 patients collected between January 2009 and August 2016.

Results: The mean age of the patients was 38 years (range: 5–79 years), with a clear male predominance (74%). Etiologies were dominated by penetrating wounds, particularly assaults (56.5%), followed by iatrogenic causes (34.7%). PTAVFs were primarily located in the lower limbs (76.1%). The average trauma-to-diagnosis interval was 10 months. The association of a pulsating mass and thrill was the primary clinical sign in all patients. CT angiography (CTA) was the gold standard imaging modality in our series. All patients underwent surgical exclusion of the PTAVF combined with arterial and/or venous restoration. Postoperative outcomes were marked by one death, one case of deep vein thrombosis, and one case of acute lower limb ischemia. The average hospital stay was 10 days.

Conclusion: While penetrating trauma remains the main characteristic of our study population, iatrogenic origins are increasingly emerging as a significant etiology due to the advancement of invasive interventional procedures in our country.

Keywords: arteriovenous fistula – penetrating trauma – limbs

Introduction:

Although they represent a rare form of vascular trauma, PTAVFs remain serious lesions due to their pathophysiological consequences, such as congestive heart failure and arteriomegaly [1].. While primarily reported in military series, PTAVFs remain a relatively frequent form of vascular trauma in civilian practice. Furthermore, iatrogenic pathology has emerged as a frequent injury mechanism, given the development of diagnostic and therapeutic procedures involving arterial catheterization[2].

Materials and Methods: This is a retrospective study concerning 21 patients collected in our facility between 2009 and 2016. The inclusion criteria were patients presenting with an arteriovenous fistula located in a limb and occurring following a documented trauma. Post-traumatic fistulas in other territories

and congenital fistulas were excluded. The study was conducted using a standardized data collection sheet, accounting for epidemiological data (age, sex, mechanism), clinical data (delay, affected side, topography, and symptoms upon admission), as well as paraclinical, therapeutic, and follow-up data.

Results:

Our series included 15 men and 6 women, with a mean age at the time of diagnosis of 38 years (range: 5–79 years). Initial trauma was primarily related to knife assaults in 47.6% of patients, followed by iatrogenic origins in 38.1% of cases. The mean interval between the initial injury and diagnosis was 10 months (ranging from 2 hours to 9 years).

In our series, vascular involvement was predominantly located in the lower limbs (16 cases, or 76.1%), followed by the upper limbs (5 cases, or 23.9%). The anatomical distribution of the PTAVFs is detailed in Table I.

Table I. Anatomical Distribution of AVFs in the Limbs

Vessels	Number of cases	Percentage
Brachial	1	4.8%
Radial	3	14.8%
Ulnar	1	4.8%
Common Iliac	1	4.8%
Common Femoral	6	19%
Superficial Femoral	7	23.8%
Deep Femoral	2	9 ,5%
Popliteal	4	19%

The clinical presentation at admission was dominated by the presence of a pulsating mass (90.5%) and a palpable thrill (85.7%). Furthermore, the association of these two clinical signs was found in 52% of patients, with limb ischemia being associated in 13% of cases. A systolic-diastolic murmur was auscultated in 62% of the cases. Other signs less specific to PTAVFs were noted, but at a lower frequency (Table II).

Clinical signs	Number of cases	Percentage
Pulsating Mass	19	90,5%
Thrill	18	85,7%
Murmur	13	62%
Ischemia	4	19%
Vaicose vein	2	9,5%
Heart failure	2	9,5%
Hemorrhage	0	0

Table II. Clinical Signs at Patient Admission

All patients in our series underwent preoperative radiological exploration. Doppler ultrasound was performed in 11 cases, 4 of which were inconclusive, leading to the use of CT angiography (CTA) in 3 patients and arteriography in the fourth. CTA was performed in 12 patients: as a first-line investigation in

8 cases and as a second-line measure in 4 patients (Figure 1). Arteriography was performed in only one patient. Magnetic resonance angiography (MRA) was necessary for 2 patients due to end-stage renal disease with preserved diuresis. These paraclinical investigations successfully identified an AVF in all cases, while the presence of an associated pseudoaneurysm was reported in 14 patients.

A systemic impact assessment using transthoracic echocardiography (TTE) was performed in 2 patients. In both cases, it revealed high-output global heart failure with left ventricular dysfunction, impaired ejection fraction, and the presence of pulmonary arterial hypertension.

Surgical treatment was undertaken in all patients. The mainstay of treatment was the exclusion of the AVF combined with arterial and/or venous restoration. All surgical techniques used are summarized in Table III.

Type of intervention	Number of cases	Percentage
AVF Exclusion	21	100%
Aretriovenous Fistula Repair	19	90,5%
Arterial Restoration		
Ligation	1	4,8%
End-to-End Anastomosis	5	23,8%
Lateral suture	9	42.9%
Venous Graft	3	14.3%
Prothesis	3	14.3%
Embolectomy	3	14.3%
Venous Restoration		
Ligation	6	28.6%
Suture	15	71.4%
Patch	0	0
Graft	0	0

Table III. Surgical Techniques Used in Our Series

Additional procedures associated with the primary surgical treatment were performed in 17 patients. These included pseudoaneurysm repair (flattening) in 90.5% of patients, decompressive fasciotomies in 2 patients with severe ischemia, and Fogarty catheter embolectomy in 3 patients.

Immediate postoperative outcomes were uneventful in 18 patients. However, we recorded one case of deep vein thrombosis, one transfemoral amputation in a single patient, and one death on postoperative day 3 following an ischemic stroke of the brainstem.

Long-term outcomes were favorable in 91.3% of cases, with a mean follow-up of 6.5 years. The amputated patient was referred to a rehabilitation and prosthetics center.

Discussion:

An arteriovenous fistula (AVF) is an abnormal communication between an artery and an adjacent vein, of either congenital or acquired origin, bypassing the distal capillary network[3]. This condition was first described in 1757 by William Hunter[4]. Although they represent a rare form of vascular trauma, AVFs remain serious lesions due to their pathophysiological consequences, such as congestive heart failure and arteriomegaly. [3].

PTAVFs have been primarily documented in military series, including World War II and the Korean and Vietnam Wars. The expertise gained from these conflicts established the foundational principles for their management; however, PTAVFs continue to present a significant diagnostic and therapeutic challenge[5]. In civilian practice, PTAVFs remains a relatively frequent manifestation of vascular trauma. Furthermore, iatrogenic pathology has emerged as a common injury mechanism due to the increasing development of diagnostic and therapeutic procedures involving arterial catheterization[2].

Various causal mechanisms can be distinguished: penetrating, blunt, and iatrogenic traumas. Our series is characterized by a predominance of penetrating trauma secondary to knife assaults (43.4%). This type of wound is the most likely to result in PTAVFs because tissue loss is minimal compared to injuries caused by high-velocity projectile fragments, which are more frequently complicated by hemorrhage[6]. Robbs et al. reported a similar etiological profile in South Africa, where knife assaults accounted for 63% of PTAVFs [7]. In contrast, in developed countries, iatrogenic causes remain the most frequent due to the advancement of diagnostic and therapeutic procedures involving arterial catheterization[8,9]. Amrani et al. reported that iatrogenicity accounted for 75% of etiologies in Belgium [10]. Anamnestic data often allow for the determination of the fistula's origin.

Schematically, the pathophysiological model to consider is an "H" configuration, consisting of an artery and a vein connected to each other by the fistula. This communication is responsible for "systemic" upstream consequences and "local" downstream consequences.

If the fistula is large, the pressure in the distal artery decreases, and the resistance of the capillary bed becomes higher than that of the fistula. This can result in a reversed and retrograde flow, leading to relative ischemia of the downstream territory [3].

The opening of an AVF leads to a sudden drop in systemic resistance, followed by a cascade of events resulting in significant cardiac repercussions[11].. Indeed, the heart responds to the arteriovenous shunt first by increasing stroke volume, and subsequently by increasing the total effective blood volume. These systemic effects are of major importance in patients with pre-existing heart disease[11, 12]. The left-to-right shunt and the heart's subsequent inability to compensate for the chronic volume increase lead to ventricular remodeling, dilation, and eventually heart failure[13, 14].

Subjective symptoms, such as a sensation of internal beating or thrill, should be systematically sought. A pulsating mass and an associated thrill, with or without a systolic-diastolic murmur, are the most frequent and nearly pathognomonic signs. Signs of stasis, limb ischemia, and pulsating varicose veins have also been described[7]. Systemic repercussions—such as a decrease in heart rate upon temporary occlusion of the fistula (Branham's sign), widening of the pulse pressure, and heart failure—were found in only two patients in our series. In chronic cases, the feeding artery of the AVF develops aneurysmal changes. These aneurysms can continue to evolve independently, even after the exclusion of the fistula [15].

In emergency settings, arterial Doppler ultrasound can be a valuable diagnostic aid. It reveals increased velocity in the upstream artery and at the arteriovenous communication, where a pulsatile flow is observed[16,17].. While Doppler ultrasound can identify the fistula, it is not sufficient on its own to determine the subsequent management plan[18]. Therefore, recourse to arteriography—the gold standard examination—is necessary whenever possible[7]. This examination provides a mapping of the lesion and offers precise information regarding peri-fistular arterial and venous changes. It also has the advantage of allowing for therapeutic intervention in certain cases[20].

However, arteriography does not visualize the relationship with surrounding structures or a thrombosed pseudoaneurysm. In such instances, computed tomography (CT) or, preferably, magnetic resonance

imaging (MRI) is superior, as they allow for a better study of the soft tissues and the relationship between the AVF and neighboring structures. Additionally, MRI enables the estimation of the various flows within the AVF.

In our series, the delayed diagnosis of post-traumatic AVFs was responsible for two cases of heart failure. In these cases, TTE revealed high cardiac output, ventricular dysfunction, and pulmonary arterial hypertension (PAH). This is consistent with the literature, which describes heart failure as a serious but rare complication of post-traumatic AVFs. Reported incidences range from 1% to 8%, depending on the shunt width, its proximity to the heart, and the duration between the initial injury and its discovery [21].

Spontaneous involution of small PTAVFs has been reported. Observation and monitoring have become a standard therapeutic approach for a large proportion of post-angiography AVFs. Indeed, the natural history of post-catheterization AVFs appears to differ from those resulting from violent or penetrating trauma [22]. Since the original article by Kotval et al. [23], several studies have suggested the possible spontaneous regression of a proportion of post-catheterization AVFs without any form of intervention [24–25]. In contrast, non-iatrogenic PTAVFs seem to have a rather unfavorable natural history, always necessitating prompt intervention [15, 26, 27].

Surgery remains the treatment of choice for PTAVFs. It involves isolating the vessels supplied by the fistula, disconnecting the communication, and finally restoring arterial and venous continuity. Conservative surgical methods, such as lateral suture and the interposition of venous or prosthetic grafts, are currently adopted, especially when the fistula involves a main trunk. Upstream and downstream ligation may be proposed when the lesion is located on a secondary trunk or a collateral branch. The main difficulty during this surgery is achieving hemostasis of the venous structures. The surgeon is sometimes forced to perform vascular sutures in a hemorrhagic environment, while the assistant strives to ensure hemostasis. Consequently, the use of an Esmarch bandage is recommended, as it eliminates one of the primary technical difficulties of this procedure [5].

When lesions are diffuse or difficult to locate, arterial embolization is a safe and effective therapeutic alternative [28]. If the AVF is iatrogenic, embolization can be performed during the same procedure [29].

Endovascular treatment using endoprostheses or "covered stents" is a minimally invasive technique that has the advantage of preserving both arterial and venous continuity. This treatment avoids the dissection of the vessels supplied by the fistula, thereby reducing the risk of nerve, arterial, and venous injuries [30,31]. However, the long-term effectiveness of this treatment remains insufficiently evaluated to be recommended for non-iatrogenic PTAVFs. This is particularly true given the concerns regarding the placement of foreign material in a potentially septic environment, as well as the long-term patency of these endoprostheses in small-caliber arteries in typically young patients. Regardless of the type of treatment, patients must be monitored to detect any potential aneurysmal degeneration[15].

Conclusion :

Post-traumatic arteriovenous fistulas are uncommon but serious lesions that can jeopardize both the functional and vital prognosis of patients due to their hemodynamic consequences, particularly congestive heart failure. Early diagnosis followed by adequate management is recommended and helps prevent severe complications. Surgical closure remains the treatment of choice; however, other alternatives such as covered stents and embolization are intended for patients at high operative risk.

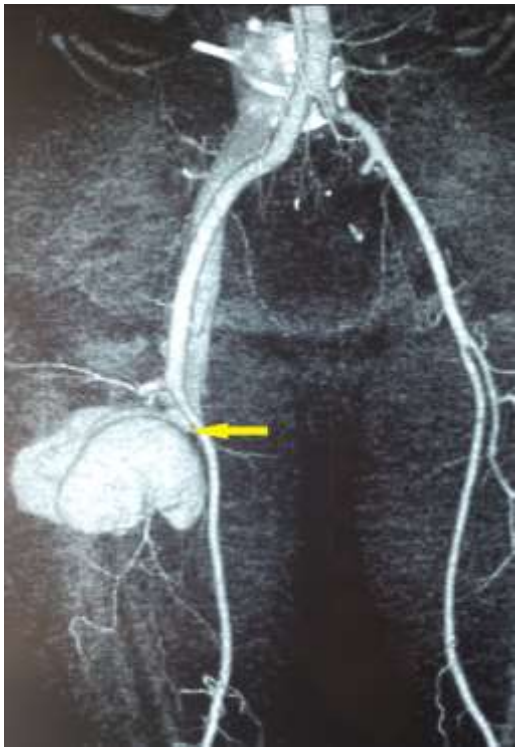

Figure 1 : femoro-femoral fistula associated with a false aneurysm

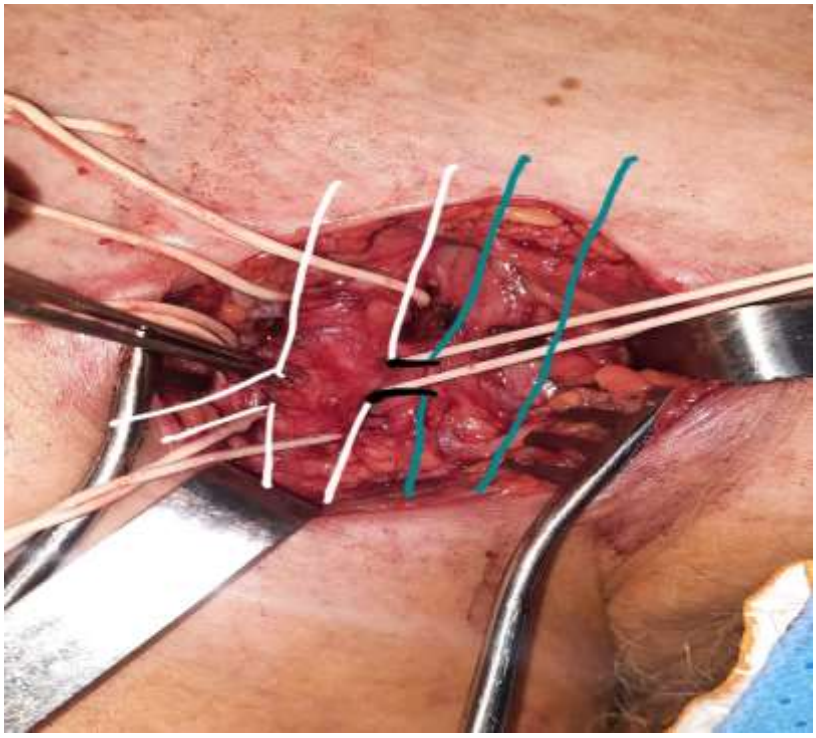

Figure 2 : The H-shaped Appearance between Commun femoral artery and femoral vein

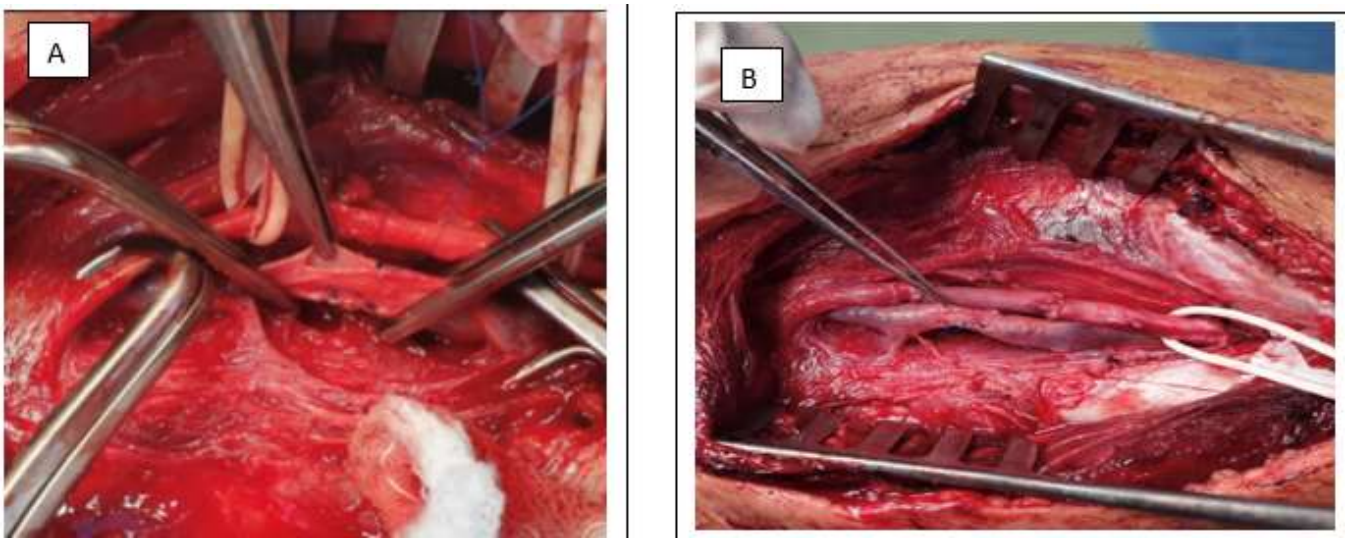

- Operative view showing a through-and-through wound of the superficial femoral vein.
- Operative view after restoration of arterial continuity with a reversed saphenous vein graft, along with simultaneous repair of the underlying femoral vein.

References:

1. BOKHABRINE MK, BENSAID Y. Fistules artério-veineuses post traumatiques des membres, thèse de Médecine N : 170 Rabat 2001.
2. Ricco JB, Febrer G. Traumatismes vasculaires des membres, EMC, Techniques chirurgicales-chirurgie vasculaire, 2006. 43-025.
3. Kassabian E, Sleilaty G, Jebara V. Fistules artérioveineuses acquises. EMC – Cardiologie 2006:1-6.
4. Hunter W. Observation up on a particular species of aneurysm. Med Obs Soc Phys 1762.2.390.
5. Lebreton G, Uzel A-P, Celerien J, N'Guyen R, Deneuville M. Fistule Artério-Veineuse poplitée secondaire à une plaie par arme à feu : A propos d'un cas, revue de la Littérature. Ann Chir Thorac Cardiovasc 2008 ; 12 : 120-5.
6. Baker WH. Arteriovenous fistulae of the aorta and its major branches. In: Rhutherford RB, editor. Vascular surgery. Philadelphia: WB Saunders; 1995. p. 1207–11.
7. Robbs JV, Carrim AA, Kadwa AM, Mars M. Traumatic arteriovenous fistula: experience with 202 patients. Br J Surg. 1994 Sep; 81(9):1296-9.
8. White JJ, Talbert JL. Peripheral arterial injuries in infants and children. Ann Surg 1965;167:757–65.
9. Shifrine G, Anner H. Arteriovenous fistula in lower limb after Fogarty ballon catheter embolectomy. J Cardiovasc Surg (Torino) 1985; 26:310–3.
10. AMRANI M, RENOIRTE P, FIEVEZ R. Fistule artérioveineuse traumatique, Experience de 9 cas. J Mal Vasc.1991;16,234-237.
11. Nakayama DK. Arteriovenous Fistula: The Backstory of the Birth of Cardiovascular Surgery. J Surg Educ. 2016 Nov - Dec;73(6):1085-1092.
12. Sumner DS. Hemodynamics and pathophysiology of arteriovenous fistulae. In: Rutherford RB, editor. Vascular Surgery. 5th edition. Philadelphia, Pa, USA: W. B. Saunders; 2000.
13. Weng C-F, Wei J, Lee Y-T, Sue S-H, Chuang Y-C, Chang C-Y, et al. High-output Heart Failure Resulting from an Obscure Traumatic Arteriovenous Fistula. J Chin Med Assoc 2008 Vol 71, No 8.
14. Engelberts I, Jan H.M. High-output cardiac failure due to excessive shunting in a hemodialysis access

fistula: an easily overlooked diagnosis. Academic hospital. Maastricht. The Netherlands. Am J Nephrol 1995;15(4):323-6.
15. Melliere D, Saada F, Becquemin JP. Le risque anévrismal. Autre raison d'opérer les fistules artério-veineuses traumatiques. J Mal Vasc 1987;12-3:277–9.
16. Strandness DE, Summer DS. Arteriovenous fistulas. In hemodynamics for surgeons. New York: Grune and Stratton; 1975. p. 621–663.
17. Barnes RW. Noninvasive assessment of arteriovenous fistula. Agiology 1978;29:691.
18. Jebara, El rassi. Fistules artérioveineuses acquises. Encycl Med Chir, Angeiologie 1987;19- 1720:8.
19. Bokhabrine MK, Bouziane Z, Lahlou Z, Lekhal B, Bensaid Y. Annales de Cardiologie et
1. d'Angéiologie 59 (2010) 67–7.
20. Rhutehrford RB, Summer DS. Diagnostic and evaluation of arteriovenous fistulae. In: Rhutherford RB, editor. Vascular surgery. Philadelphia: WB Saunders; 1995. p. 1192–207.
21. Huang W, Villavicencio JL, Rich NM. Delayed treatment and late complications of a traumatic arteriovenous fistula. J Vasc Surg 2005; 41: 715-7.
22. Toursarkissian B, Allen BT, Petrinec D, Thompson RW, Rubin BG, Reilly JM, et al. Spontaneous closure of selected iatrogenic pseudoaneurysms and arteriovenous fistulae. J Vasc Surg 1997; 25(5):803–8.
23. Kotval PS, Khoury A, Shah PM, Babu SC. Doppler sonographic demonstration of the progressif spontaneous thrombosis of pseudoaneurysm. J Ultrasound Med 1990; 9:185–90.
24. Kresovic TF, Khoury MD, Miller BV, Winniford MD, Shamma AR, Sharp WJ, et al. A retrospective study of the incidence and natural history of femoral vascular complications after percutaneous transluminal coronary angioplasty. J Vasc Surg 1991; 13:328–36.
25. Paulson EK, Hertzberg BS, Paine SS, Carroll BA. Femoral artery pseudoaneurysms: value of color Doppler sonography in predicting which ones will thrombose without treatment. AJR Am J Roentgenol 1992; 159:1077–81.
26. Winegarner FG, Baker Jr AG, Bascom JF, Jackson GF. Delayed vascular complications in Viet-Nam casualties. J Trauma 1970; 10:867–73.
27. Escobar GA, Escobar SC, Marquez L, Fink C, Cardenas F, Maldonado H, et al. Vascular Trauma: late sequelae and treatment. J Cardiovasc Surg (Torino) 1980; 21:35–40.
28. Schmidz B, Bahtt GM. Management of post traumatic vascular malformations by catheter embolisation. Ann Surg 1980; 140:332–5.
29. Ananthakrishnan G, DeNuzio M, Bungay P, Pollock G, Fishwick G, Bolia A. The occurrence of arterio-venous fistula during lower limb subintimal angioplasty: treatment and outcome. Eur J Vasc Endovasc Surg 2006; 32:675–9.
30. Marin ML, Veith FG. Percutaneous transfemoral insertion of a stent graft to repair traumatic arteriovenous fistula. JVS 1993; 18(2):299–302.
31. Donnald T, Baril, Paula I. Endovascular repair of a traumatic arteriovenous fistula 34 years after injury. Report of a case. Surg Today 2007; (37):78–81.