

Digital Orthopantomographic Analysis of Mandibular Foramen Position in Indian Population

Dr. Daya Shankar¹, Dr. Shobhana Chandra², Dr. Prachi K³,
Dr. Vidushi Chandra⁴, Dr. Gaurav Prakash⁵

¹Ex Assistant Professor, Dentistry, Patna Medical College & Hospital,

²Senior Endodontist, Narayan Multispeciality Dental Clinic

³Consultant Dentist, Narayan Multispeciality Dental Clinic

⁴Post Graduate Trainee, Narayan Multispeciality Dental Clinic

⁵Senior Lecturer, Department of Periodontology, Azamgarh Dental College, Azamgarh

ABSTRACT

The mandibular foramen (MF) marks the entry of the inferior alveolar nerve (IAN) into the mandibular canal and shows considerable anatomical variability, making its accurate localization clinically essential. Orthopantomogram (OPG) is a widely used panoramic imaging modality for identifying maxillofacial anatomical landmarks due to its accessibility and diagnostic efficiency. This retrospective study aimed to evaluate the anteroposterior and superoinferior position of the MF using digital OPGs in an Indian population. Quantitative measurements were obtained from anonymized digital OPG records and subjected to statistical analysis. The mean anteroposterior distance of the MF from the anterior border of the mandibular ramus was 15.96 ± 1.82 mm, with minimal right-left side variation.

Conclusion: Digital OPG is a reliable and accurate modality for determining the location of the MF based on anteroposterior and superoinferior measurements. The findings are clinically relevant for improving the success of inferior alveolar nerve block anesthesia and for aiding preoperative planning in mandibular orthognathic surgeries and ramus osteotomies, thereby reducing procedural complications.

KEYWORDS: Anatomic landmark, Inferior alveolar nerve, Orthopantomogram, Mandibular foramen, Inferior alveolar nerve block.

INTRODUCTION

A clear understanding of the anatomical configuration and pathway of the mandibular canal is fundamental for performing dental and maxillofacial procedures safely. The mandibular canal contains the inferior alveolar neurovascular bundle, which supplies sensory innervation to the mandibular dentition. Entry of this neurovascular structure occurs through the mandibular foramen (MF), located on the medial surface of the mandibular ramus. The inferior alveolar nerve (IAN), a branch of the posterior division of the mandibular nerve, enters the canal through this foramen and travels anteriorly within the mandible until it exits through the mental foramen as the mental nerve^{1,2}. Superior to the mandibular foramen lies the lingula, a triangular bony projection that serves as an important anatomical landmark during mandibular

surgical procedures¹⁻³.

Among dental anesthetic techniques, the inferior alveolar nerve block (IANB) is one of the most frequently performed procedures. The success of this technique largely depends on the accurate deposition of anesthetic solution near the mandibular foramen within the pterygomandibular space. However, the failure rate of this block has been reported to range from 15% to 25%, which is often attributed to inaccuracies in identifying anatomical landmarks³⁻⁵.

Radiographic evaluation plays an essential role in the identification of anatomical structures within the maxillofacial region. Several imaging techniques are used in dental practice, including intraoral radiographs, lateral cephalograms, orthopantomograms (OPG), and cone-beam computed tomography (CBCT). Among these, OPG is widely utilized because it provides a comprehensive panoramic image of the maxilla, mandible, temporomandibular joints, and dentition in a single radiograph⁵.

In contrast, CBCT offers three-dimensional visualization of craniofacial structures and enables highly precise measurements through volumetric reconstruction. This imaging modality provides accurate representation of anatomical structures without the distortion. However, its higher cost, limited accessibility, and greater radiation exposure compared with panoramic radiography may restrict its routine use in some clinical settings. Despite these limitations, several studies have demonstrated that digital OPG can provide reliable measurements for the localization of anatomical landmarks such as the mandibular foramen^{6,7}. These findings suggest that digital OPG remains a practical and dependable imaging method for identifying critical mandibular landmarks, particularly in situations where CBCT is not readily available.

Therefore, the present study aimed to determine the anteroposterior and superoinferior position of the mandibular foramen using digital OPG in an Indian population, with the objective of providing clinically relevant information for dental practitioners and oral surgeons.

MATERIAL AND METHODS

The present investigation was designed as a retrospective radiographic study utilizing orthopantomographic (OPG) records of patients who attended various dental clinics in Bihar, India, for diagnostic and therapeutic purposes. A total of 120 patient radiographs were randomly selected from the database of a radiology center.

The inclusion criteria comprised individuals aged 18 years and above with no evidence of facial asymmetry, pathological lesions, mandibular fractures, or previous mandibular surgery. Patients were required to have at least three-fourths of their natural dentition present, including bilateral mandibular first and second molars with corresponding maxillary molars, in order to minimize measurement variations associated with supra-eruption. Radiographs exhibiting severe occlusal wear or patients with a history of uncontrolled systemic disease were excluded from the study. Each selected participant was assigned a sequential identification number according to the chronological order of registration at the radiology center. The diagnostic quality of all digital OPGs was evaluated by an experienced oral radiologist prior to analysis. Radiographs deemed unsuitable for evaluation were excluded, and additional radiographs were randomly selected based on the predefined inclusion criteria to maintain the required sample size. All panoramic radiographs were acquired using a digital panoramic radiography unit (Vatech A9, Gyeonggi-do, Korea) operating at 120 kVp, with a maximum tube current of 10 mA and an exposure time of 12 seconds.

Ethical approval

This investigation was designed as a retrospective observational radiographic study utilizing previously recorded imaging data. As the study did not involve any direct patient contact, clinical intervention, or alteration in patient management, it posed minimal risk to the participants and adhered to established ethical principles for observational research. All radiology datasets were anonymized prior to analysis to ensure patient confidentiality and compliance with applicable ethical standards and data protection regulations

Image Acquisition

During radiographic acquisition, patients were positioned according to the standard panoramic imaging protocol. Patients were instructed to stand upright and maintain stability by holding the unit handles. The chin rest and positioning guides were adjusted to achieve proper occlusal plane inclination and sagittal alignment along the facial midline.

Radiographic Reference Points and Measurements

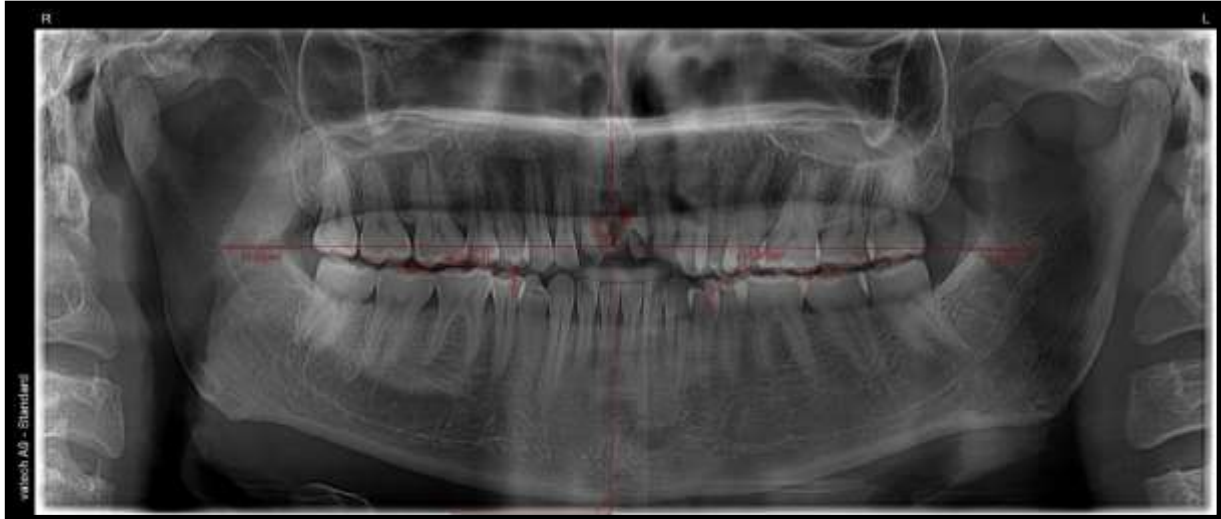
Localization of the mandibular foramen (MF) on orthopantomograms was performed using specific radiographic reference points and digital linear measurements. All measurements were carried out on digital panoramic images using the built-in linear measurement tool available in the image analysis software (EzDent-i, Gyeonggi-do, Korea). The position of the mandibular foramen was determined in both the anteroposterior (AP) and superoinferior (SI) dimensions with reference to three anatomical landmarks: a. Anterior border of the mandibular ramus (AB) b. Anteroinferior border of the mandibular foramen (MF), c. Mandibular molar occlusal plane (OP). To determine the anteroposterior location of the mandibular foramen, a horizontal reference line (MF–AB) was drawn from the mandibular foramen toward the anterior border of the mandibular ramus, positioned perpendicular to the true vertical line (TVL). The point at which this line intersected the anterior border of the ramus was identified and labeled as AB. For identification of the mandibular occlusal plane (OPL), a line was constructed through the cusp tips of the first and second mandibular molars. Subsequently, a vertical line parallel to the true vertical line was extended from the MF–AB reference line downward until it intersected the occlusal plane at the level of the mesial cusp of the first mandibular molar, which was designated as OP^{6, 8}.

Based on these reference landmarks, two linear measurements were obtained digitally:

1. MF–AB distance, representing the anteroposterior position of the mandibular foramen relative to the anterior border of the ramus.
2. MF–OP distance, representing the superoinferior position of the mandibular foramen relative to the occlusal plane.

These measurements were recorded and subsequently analyzed with respect to independent variables including age, sex, and anatomical side (right or left) in order to evaluate the positional variation of the mandibular foramen in the Indian population (Fig.1).

Figure 1. OPG showing digital measurements of mandibular foramen (MF): horizontal red line—anteroposterior position (mm); vertical red line—superoinferior position (mm); TVL = true vertical line; superior red line = perpendicular from MF to TVL; inferior red line = occlusal plane



Statistical Analysis

Statistical analysis was performed using SPSS software version 23.0 (IBM Corp., Armonk, NY, USA). Data were expressed as mean ± standard deviation, and statistical significance was set at $p < 0.05$. Normality and homogeneity of variance were assessed using the Shapiro–Wilk and additionally, Levene’s test was applied to verify the homogeneity of variances among the groups before conducting parametric comparisons.

RESULTS

The anteroposterior measurements of the mandibular foramen demonstrated slight variation between the right and left sides. The mean distance on the right side was 16.12 mm (SD = 1.63), while the left side showed a slightly lower mean value of 15.80 mm (SD = 2.01). The pooled mean anteroposterior distance was 15.96 mm with a standard deviation of 1.82 (Table 1).

Similarly, the superoinferior measurements revealed minor side-wise differences. The mean value on the right side was 5.66 mm (SD = 3.06), whereas the left side demonstrated a slightly higher mean of 6.28 mm (SD = 3.08). The overall pooled mean superoinferior distance was 5.97 mm with a standard deviation of 3.07 (Table 2). The relatively higher standard deviation observed in the superoinferior measurements may reflect inter-individual anatomical variation and the inherent difficulty in precise identification of superoinferior landmarks on panoramic radiographs, despite standardized imaging and measurement protocols.

Table 1. Anterio posterior measurements of mandibular foramen

Variable	Mean	Std. Error	Std. Deviation	Variance
Right Side	5.66	0.395	3.060	9.363
Left Side	6.28	0.398	3.083	9.507
Overall	5.97	0.3965	3.0715	9.435

Table 2. Superio inferior measurements of mandibular foramen

Variable	Mean	Std. Error	Std. Deviation	Variance
Right Side	16.12	0.210	1.627	2.647
Left Side	15.80	0.260	2.014	4.056
Overall	15.96	0.235	1.8205	3.3515

DISCUSSION

Radiographic imaging is fundamental in dental diagnostics and oral and maxillofacial surgical planning. Several imaging modalities—including orthopantomography (OPG), lateral cephalograms, intraoral periapical radiographs, and cone-beam computed tomography (CBCT)—are commonly used to evaluate craniofacial structures and guide treatment procedures. The present study was undertaken based on the premise that OPG can effectively localize important anatomical landmarks, including the mandibular foramen (MF). A total of 120 patient radiographic records fulfilling the predefined inclusion criteria were included in the study. As this was a retrospective observational study based on the availability of eligible archived radiographic records, a formal prospective sample size calculation was not performed. However, a pilot assessment was undertaken prior to the main analysis to evaluate measurement reliability, which demonstrated excellent intra-examiner agreement and confirmed the reproducibility of the measurement protocol. All measurements were obtained directly from digital radiographs using radiographic image analysis software. The use of digital panoramic images improved the precision and reproducibility of the measurements obtained. These observations are consistent with the findings reported by Yasser S. Alali et al. (2025)⁶ who concluded that digital OPG is a reliable imaging technique for determining the position of the mandibular foramen. Their study highlighted its usefulness in assessing both the anteroposterior relationship of the MF with the anterior border of the mandibular ramus and its superoinferior position relative to the mandibular occlusal plane, with results comparable to those obtained using CBCT imaging. Other methodologies have also been described in the literature. Trost et al (2010)⁴, Patil et al. (2015)⁹ & Kaur et al (2022)¹⁰ who evaluated the accuracy of OPG in determining the position of the mandibular foramen by comparing radiographic measurements with direct measurements obtained from dry mandibles. Collectively, these investigations support the use of OPG as a reliable method for identifying the mandibular foramen, although image magnification remains a limitation that should be taken into account during interpretation. The findings of the present study, derived from digital OPG analysis, demonstrated that the mean anteroposterior distance of the mandibular foramen (MF) from the anterior border of the mandibular ramus in the studied Indian population was 15.96 ± 1.82 mm, with only minor variations between the right and left sides. These results correspond closely with previously reported morphometric investigations on dry human mandibles from the Indian subcontinent, including studies by Samanta & Kharb (2013)¹¹, Padmavathi et al (2014)¹², Shalini R. et al (2016)¹³ & Singh Y. et al (2025)¹⁴. However, slight differences were observed when comparing. The present measurements with those reported by Gopalakrishna et al (2016)¹⁵. These variations may be explained by differences in sample size, study design, and the specific anatomical reference points used for measurement of mandibular dimensions.

CONCLUSION

The current study offers a reasonable understanding in determining 120 the precise radiographic location of the mandibular foramen in the Indian population that provides valuable clinical guidance for dental

professionals. Accurate localization not only minimizes the risk of neurovascular injury and associated complications such as paresthesia and hemorrhage but also enhances the success rate of local anesthesia. Furthermore, interpretation of the mandibular foramen on OPG serves as an important reference for oral and maxillofacial surgeons in surgical planning and for radiotherapists in optimizing radiation delivery while preserving vital structures.

Future aspect

Future studies should incorporate advanced imaging techniques such as CBCT, CT or 3D analysis to enable larger sample sizes will improve measurement accuracy and enhance reliability. While inclusion of mandibles from diverse populations and ethnic group would strengthen the generalizability of the findings. The use of artificial intelligence in coordination with emerging radiographic technologies to simplify image acquisition and data synthesis is an area to be considered for future research.

REFERENCES

1. De Castro R.W.Q, Marlière D.A.A, Haiter Neto F, Groppo F.C, Asprino L. Positions of the Mandibular Foramen and Canal in different Skeletal Classes and Implications for Bilateral Sagittal Split Osteotomy. *J. Maxillofac. Oral Surg.* 2024.
2. Mathew A, Mohan N. Prevalence, length, and patterns of Anterior Loop among the South Indian population: A comparative study between Panoramic Radiography and Cone Beam Computed Tomography. *Porto Biomed. J.* 2023; 8, e216.
3. Kaur R, Singla R.K, Sharma R, Singla, S. Localization of mandibular foramen—A comparison between dry bones and orthopantomogram. *J. Med. Life* 2022; 15, 669–674.
4. Trost, O, Salignon V, Cheynel N, Malka G.; Trouilloud, P. A simple method to locate mandibular foramen: Preliminary radiological study. *Surg. Radiol. Anat. SRA* 2010, 32: 927–931.
5. Maoxia,W, Anchun, M. A digital workflow for the inferior alveolar nerve block in the edentulous mandible. *J. Prosthet. Dent.* 2023; 130, 141–145.
1. 6.Alali YS, Mohammed W.A, Alotaibi S.M, Alshehri S, 206 Alshayban M. Accuracy of Mandibular Foramen Localization Using Digital Orthopantomogram (OPG) in Middle Eastern Population. *Diagnostics* 2024;14, 2173.
6. Chen, C.M.; Lee, H.N.; Chen, Y.T, Hsu, K.J. Locating the Mandibular Lingula Using Cone-Beam Computed Tomography: A Literature Review. *J. Clin. Med.* 2023; 12, 881.
7. Zhang, J, Jiang, Y, Gao, F.; Zhao, S,Yang, F, Song, L. A Fast Automatic Reconstruction Method for Panoramic Images Based on Cone Beam Computed Tomography. *Electronics.*2022; 11, 2404.
8. Patil, K, Guledgud, M.V.,Bhattacharya, P.T. Reliability of Panoramic Radiographs in the Localization of Mandibular Foramen. *J. Clin. Diagn. Res. JCDR.* 2015 :(9) ZC35–ZC38.hmm
9. Kaur R, Singla RK, Sharma R, Singla S. Localization of mandibular foramen – a comparison between dry bones and orthopantomogram. *J Med Life.* 2022 May;15(5):669-674.
10. Samanta PP, Kharb P. Morphometric analysis of mandibular foramen and incidence of accessory mandibular foramen in adult human mandibles of an Indian population. *Rev Arg De Anat Clin.* 2013, 5:60-6. 10.31051/1852.8023.v5.n2.14059.
11. Padmavathi G,Tiwari S, Varalakshmi KL, et al An anatomical study of mandibular and accessory mandibular foramen in dry adult human mandibles of South Indian origin.*IOSR-JDMS.* 2014,13:83-8.

12. Shalini R, RaviVarman C, Manoranjitham R, Veeramuthu M: Morphometric study on mandibular foramen and incidence of accessory mandibular foramen in mandibles of south Indian population and its clinical implications in inferior alveolar nerve block. *Anat Cell Biol.* 2016, 49:241-8. 10.5115/acb.2016.49.4.241
13. Singh Y, Shakya P, Saba N, et al. A Morphometric Study of the Mandibular Foramen, Lingula, and the Incidence of Accessory Mandibular Foramina in Dry Mandibles. *Cureus* 17(3).2025: e81087. DOI 10.7759/cureus.81087
14. Gopalakrishna K, Deepalaxmi S, Somashekara SC, Rathna BS: 235 An anatomical study on the position of mandibular foramen in 100 dry mandibles. *Int J Anat Res.* 2016, 4:1967- 71. 10.16965/ijar.2016.122